

## The Tendon Treatment Center: New Horizons in the Treatment of Tendinosis

James P. Tasto, M.D., Jeffrey Cummings, M.D., Virgil Medlock, M.D.,  
Frederick Harwood, Ph.D., Renee Hardesty, L.V.N., and David Amiel, Ph.D.

**C**onservative care for the treatment of chronic tendinosis is well known to the reader. It consists of rest, ice, compression, and elevation in the acute phase. This is followed with physical therapy, activity modification, bracing, cortisone injections, topical applications, as well as oral nonsteroidal anti-inflammatory drugs (NSAIDs). Other homeopathic approaches have been used that consist of procedures such as acupuncture and items such as magnets.

When conservative care fails, surgical intervention is oftentimes contemplated. It is not always rewarding as a result of the difficulty in addressing the specific area involved, potential complications, and oftentimes long rehabilitation. As surgeons, we are not always comfortable debriding a tendon or releasing a tendon, not fully understanding if we are reversing or ameliorating the condition. There has been very little to offer the patient between these conservative and surgical procedures. The use of bipolar radiofrequency microtenotomy (Topaz; Arthrocare, Sunnyvale, CA) and extracorporeal shock wave therapy (ESWT) have helped to fill this gap.

It is important for the reader to understand these 2 new therapeutic measures in depth, not only to appreciate the value of the treatment rendered the patient, but also to understand the potential economic benefit to one's practice.

Current orthopaedic research and potential future applications for the use of bipolar radiofrequency will stem from its ability to stimulate angiogenesis and help regulate a variety of growth factors such as

vascular endothelial growth factor (VEGF) and  $\alpha$ -V-integrin. The use of this technology probably produces a controlled injury, stimulates a biologic response, and (at least in the clinical setting) appears to interfere with the nociceptors at a cellular level. There are a wide variety of potential future orthopaedic applications for this technology, if the basic science and clinical research outcomes continue to be as favorable as they have been to date. They would consist of enhancing meniscal repair, reversing rotator cuff tendinopathy, enhancing the angiogenic response in the repair of compromised tissue, and pain control.

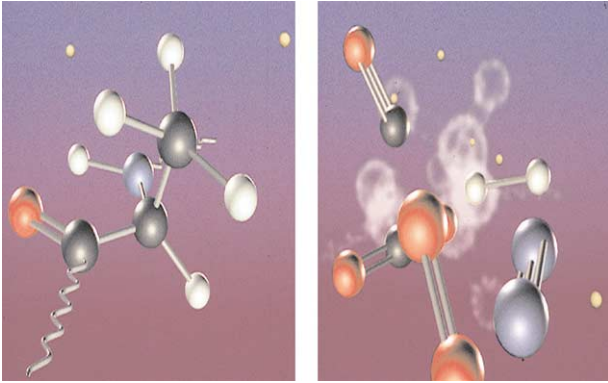
### **RADIOFREQUENCY MICRODEBRIDEMENT: A NOVEL TREATMENT OPTION FOR TENDINOPATHIES**

Radiofrequency (RF) currents have been used successfully in a variety of medical applications. Traditionally, tissue has been denatured, desiccated, and vaporized through heat-generated mechanisms. Recently, a novel bipolar RF technique for volumetric tissue removal has been introduced. Coblation technology is fundamentally different from traditional electrocautery and thermal devices. Under appropriate conditions, a small vapor layer forms on the active electrode(s) of the device. The electrical field on the energized electrodes causes an electrical breakdown of the vapor, producing a plasma, that is itself an electrically conducting gas consisting of free electrons, ions, and neutral chemical radicals and other neutral species (Fig 1).<sup>1</sup> The particles contained in this plasma have sufficient energy to break down most bonds formed in soft tissue molecules. The plasma is a very reactive medium in which the water molecules are broken down into excited H and OH radicals.<sup>1,2</sup> Although these molecules have a half-life of the order

---

*Address correspondence to James P. Tasto, M.D., 6719 Alvarado Rd, Suite 200, San Diego, CA 92120, U.S.A.*

*© 2003 by the Arthroscopy Association of North America  
0749-8063/03/1910-0129\$30.00/0  
doi:10.1016/j.arthro.2003.10.004*



**FIGURE 1.** Molecular dissociation caused by particles in the plasma field.

of a nanosecond, they are biologically very active.<sup>3</sup> Similar plasma technology is also used to alter microorganisms or purify water.<sup>4</sup> First used in arthroscopic surgeries, Coblation has been introduced in a number of other procedures, including cosmetic, otolaryngologic, spine, cardiac, neurosurgical, gynecologic, and urologic surgeries.

### HEALING RESPONSE AFTER COBLATION TREATMENT

Peer-reviewed publications as well as anecdotal data support faster healing response with Coblation techniques. A cosmetic surgery patient treated with Coblation healed faster than with laser surgery, as did patients undergoing tonsillectomy with Coblation versus traditional techniques.<sup>5-8</sup> Interestingly, the results of a study in which a small percutaneous Coblation device was used to treat low back pain in patients with contained herniated lumbar disk suggest that some mechanism in addition to volumetric removal of tissue might explain the quality of the clinical outcomes.<sup>9</sup>

Cardiology studies lend support to this possibility. A Coblation catheter developed to improve myocardial perfusion in patients experiencing congestive heart failure showed positive clinical outcomes in a multicenter clinical study performed in the United States and Europe.<sup>10</sup> Porcine studies were performed with a catheter that was percutaneously introduced in the ventricular cavity. The tip was positioned against the endocardium under fluoroscopic guidance and then activated with a 200V RMS RF signal for 400 ms. Histologic observation of the lesions showed that although only very small lesions were formed, they were sufficient to trigger a “healing” response as

measured by significant increases in VEGF production, creation of local microvessels, and increases local perfusion.<sup>11</sup> Improved vascularity can be a significant factor in healing, as we will discuss in the next section.

### PATHOLOGY OF TENDINOSIS

Tendon injuries observed after physical overloading or overuse are very common in athletes, as well as those involved in recreational sports or repetitive motion activities. Injuries most commonly involve the lateral and medial epicondyles of the elbow, as well as rotator cuff, Achilles and patellar tendons. Until recently, many of these tendinopathies were mislabeled as tendonitis, an inflammatory process. Lesions caused by chronic overuse are now commonly called “tendinosis” and are not considered inflammatory in nature. The pathology of tendinosis is linked to degradation of collagen and hypercellularity.<sup>12,13</sup> Normal tendons are characterized by a well-organized collagenous fibrillar network sparsely interspersed with fibroblastic cells and vascular structures. Alfredson and Lorentzon showed that tendons experiencing tendinosis contained no inflammatory cells but exhibited changes in the collagen fiber ultrastructure.<sup>14</sup> The precise etiology of the condition is still unknown, but theories range from overuse to degenerative processes.

Vascularity has been proposed to be a factor in tendon pathology. Ahmed et al. postulated that tendon rupture frequently occurs in areas that are hypovascular.<sup>15</sup> It has been hypothesized that the lack of vascularity compromises the nutrition required by tendon cells, making it more difficult for those cells to synthesize the extracellular matrix necessary for repair and remodeling of fatigue-damaged tendon. In support of this concept, Kraus-Hansen et al. showed experimentally that intratendinous ligation of blood vessels in the superficial digital flexor tendon of horses led to necrosis and fibrillation at the core of the tendon.<sup>16</sup>

Two classes of proteins, the integrins and the growth factor family of cytokines, contribute to endothelial cell migration and angiogenesis, which are important to wound healing. One subset of the integrin proteins, containing the  $\alpha_v$  subunit, has been associated with endothelial cell migration and indirectly tied to angiogenesis.<sup>17,18</sup> In the growth factor family of proteins, the VEGF has been reported to be involved in the induction and regulation of angiogenesis through its stimulatory effect on endothelial cells.<sup>19-21</sup>

Treatments for tendinosis include activity modifi-

cation, NSAIDs, corticosteroid injections, bracing, physical therapy, surgical debridement, and ESWT. A common objective in treatment options is to limit tissue injury and stimulate a healing response of which angiogenesis is a vital part.

### HYPOTHESIS

Bipolar RF treatment has the potential to induce a healing response that could reduce symptoms associated with tendinosis.

We describe a series of studies focused on the validity of 3 hypotheses: (1) tendons affected by tendinosis have poor vascularity, and therefore reduced capacity to heal and repair themselves; (2) plasma-induced radiofrequency (Coblation) has the ability to trigger tissue healing through a controlled inflammatory response; and (3) when applied to tendons affected by tendinosis, Coblation can induce healing of the tissue and reduce clinical symptoms.

#### STUDY 1: VASCULARITY OF ROTATOR CUFF TENDONS

Samples of normal and torn rotator cuff supraspinatus were harvested to assess the relative expression levels of 2 angiogenic markers. VEGF has been reported to be involved in the regulation and induction of angiogenesis through its stimulatory effect on endothelial cells.  $\alpha_v$  integrin subunit has been associated with endothelial cell migration and indirectly tied to angiogenesis. The hypothesis was that a reduction in angiogenic markers might play a role in tendon healing.

#### Materials and Methods

Biopsies of the supraspinatus tendon were obtained in patients undergoing open or arthroscopic shoulder surgery. Harvested tendons were pulverized in liquid nitrogen and total RNA was isolated using the acid-guanidium-thiocyanate-phenol extraction procedure. Extracted RNA reversed transcribed to first-strand cDNA and relative levels of  $\alpha_v$  integrin subunit and VEGF mRNA were determined by semiquantitative reverse transcriptase-polymerase chain reaction (RT-PCR).

#### Demographics

Samples were harvested from 14 subjects; 6 normal and 8 abnormal samples were obtained.

The normal samples were harvested from patients

undergoing intramedullary nailing of the humerus, shoulder replacement, open reduction and internal fixation of a proximal humerus fracture, and open anterior shoulder stabilization. Patients were between 19 and 82 years old, with a mean of 48 years.

The abnormal samples were harvested from patients with rotator cuff tears. Rotator cuff repair was performed in all patients either with an arthroscopic or with an open procedure. Patients were between 47 and 71 years old, with a mean of 61.5 years.

#### Results

Vascular endothelial growth factor was approximately a 50% lower value in abnormal samples compared with normal tissue.  $\alpha_v$  integrin subunit was approximately 30% lower in abnormal tissue compared with normal tissue.

These results show a trend for decreased expression of  $\alpha_v$  and VEGF in abnormal tissue.

#### Discussion

VEGF and  $\alpha_v$  integrin are recognized markers for angiogenesis. In accordance with the findings from Ahmed et al., torn rotator cuff tendons were found to exhibit a decrease in the expression of these angiogenesis markers.<sup>15</sup> It was reasonable to assume that a treatment modality that stimulates local blood supply and addresses the deficit of angiogenesis could enhance the ability to treat this pathologic condition.

#### STUDY 2: ANGIOGENIC RESPONSE STIMULATION IN NORMAL RABBIT ACHILLES TENDONS WITH COBLATION

A study was conducted to evaluate the effects of bipolar RF on the macroscopic and microscopic structural and cellular characteristics of the rabbit Achilles tendon and to determine if bipolar RF treatment can stimulate an angiogenic response.<sup>22</sup>

#### Materials and Methods

Seventeen New Zealand white rabbits were included in this controlled study. The Achilles tendons were treated with bipolar Coblation microdebridement using a modified ArthroCare device (Tungsten shaved ball tip 0.96 mm in diameter equipped with a 5 French arterial introducer for saline delivery) and connected to an ArthroCare System 2000 generator. Both Achilles tendons were surgically exposed (Fig 2). The left tendons were treated with Coblation with a voltage setting of 4 (175 V RMS) over a 2-cm length at

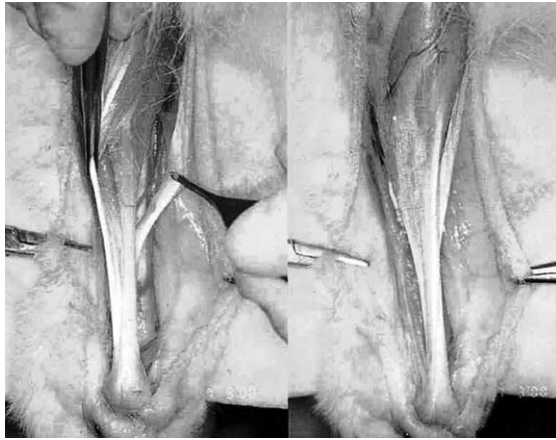


FIGURE 2. New Zealand rabbit Achilles tendon.

intervals of .5 cm. Using a custom-made timer, activation time was set to 500 ms for each application. The right Achilles tendons were touched with inactivated probes and served as sham controls. Animals were killed at 9, 28, and 90 days.

At postmortem, all tendons were examined grossly and histologic evaluation (H&E) was performed using nonpolarized and polarized light microscopy. Analysis of the angiogenic markers,  $\alpha_v$  integrin subunit, and VEGF by semiquantitative RT-PCR was carried out to determine evidence of angiogenesis. RT-PCR analysis was performed at 9 and 90 days. Statistical analysis was performed using a paired *t* test.

## Results

At 9 days, tendons treated with bipolar RF showed moderate inflammation with mild adherence to adjacent tissue and no effusion. Control tendons appeared macroscopically normal with mild adhesions between

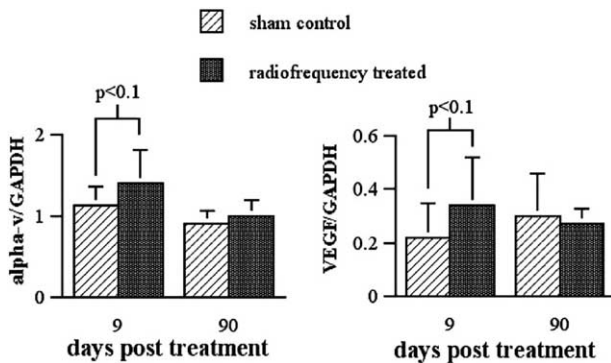


FIGURE 3. Graph depicting statistically significant increase in  $\alpha_v$ -integrin.

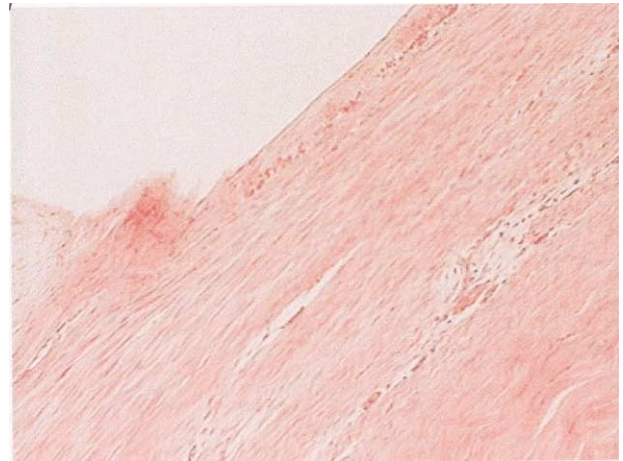


FIGURE 4. Histologic evidence of neovascularization at 28 days.

tendon bands. Histologic assessment of RF-treated tendons showed thickening of the sheath, inflammatory cells within the tendon, and a slightly disorganized collagen fiber organized and structure along with normal-appearing fibroblasts, i.e., no inflammatory cells present. RT-PCR analysis revealed an increase ( $P = .1$ ) in the  $\alpha_v$  and VEGF mRNA levels relative to controls (Fig 3).

At 28 days, RF-treated tendons exhibited minimal inflammation, no edema or effusion, and mild scarring with adherence to adjacent tissue. Histologically, RF-treated tendons contained fewer inflammatory-like cells than at 9 days but had a sheath that exhibited hypercellularity relative to sham controls. Neovascular formation was noted (Fig 4). Control tendons continued to show a normal appearance grossly and at the microscopic level.

By 90 days post-treatment, the macroscopic appearance of the treated tendons was normal with no inflammation, edema, or effusion evident. Histologically, collagen fiber organization and cellularity appeared normal. Control tendons continued to show no changes. RT-PCR analysis at 90 days demonstrated no difference in  $\alpha_v$  or VEGF expression in RF-treated tendons compared with sham controls.

## Discussion

Histologic evidence of neovessel formation and an increase in angiogenic markers demonstrated that Coblation microdebridement can increase tissue vascularity when properly applied to tendons. Although the results revealed macroscopic and microscopic changes in the early term, bipolar RF-treated tendons resumed

a normal appearance by 90 days. These results suggest that bipolar RF Coblation can provide no additional long-term morbidity and encourage additional studies to determine therapeutic relief of symptoms in humans.

### STUDY 3: PRELIMINARY RESULTS: A HUMAN FEASIBILITY STUDY IN 20 PATIENTS

A clinical pilot study has been undertaken to evaluate the safety and the effectiveness of Coblation for the treatment of tendinopathy in 20 subjects with tendinosis in the Achilles tendon, patellar tendon, and in the origin of the extensor carpi radialis (lateral epicondyle).<sup>23</sup>

#### Materials and Methods

This is a prospective, nonrandomized, single-center pilot study and proper Institutional Review Board approval was granted. Patients 18 to 65 years of age with a positive diagnosis of tendinosis of the patellar tendon, Achilles tendon, or the lateral or medial epicondyle region of the elbow were enrolled. A thorough medical history was obtained and a clinical evaluation was performed by a single surgeon. X-rays were performed to rule out any associated pathologic condition. Magnetic resonance images (MRIs) were obtained preoperatively for all patients. Patients had to be symptomatic for at least 6 months and had to have undergone and failed extensive conservative treatments. Patients with diabetes, confirmed or suspected pregnancy, prior surgical treatment for the same tendons, or osteosynthesis material close to the target tendon were excluded. Subjects under Workers' Compensation, litigation related to the injury, or patients participating in another related study were excluded.

Patients are to be followed for at least 6 months after surgery. MRI imaging results and quality of life assessment through SF 36 (36-item short form health survey) questionnaires are performed at baseline, and 4 to 6 weeks and 6 months postoperatively. Evaluation of pain was done through a visual analog scale (VAS) and by evaluating the amount of analgesic at each follow up.

Functional evaluations are performed at baseline, and 4 to 6 weeks and 6 months follow-up by an International Knee Documentation Committee (IKDC) Subjective Knee Evaluation Form for the patellar tendon group, by the Upper Limb Disability of Arm, Shoulder and Hand Outcome Measures Form for the

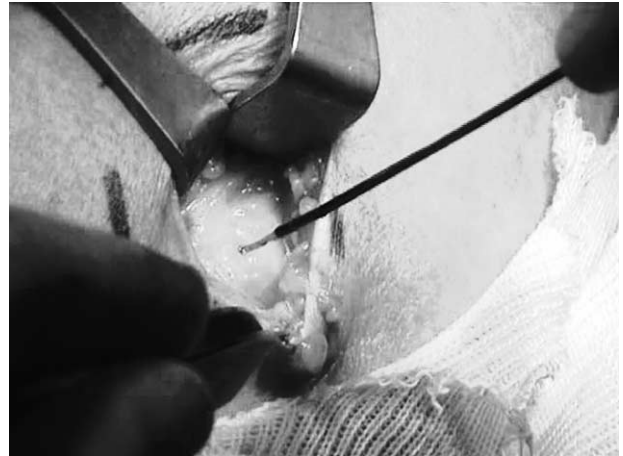

FIGURE 5. Application of Topaz on a patellar tendon.

epicondyle group, and the American Orthopaedic Foot and Ankle Society Hindfoot Evaluation for the Achilles group.

#### Surgical Procedure

The symptomatic areas were identified preoperatively while patients were still alert. After patients were placed in an appropriate position, general anesthesia was administered. A tourniquet was used and inflated to the appropriate pressure. A small incision of approximately 1¼ inch was performed over the marked symptomatic areas. The paratenon was incised where indicated to expose the involved tendon. An ArthroCare device (model Topaz) was connected to an ArthroCare system 2000 generator with a voltage setting of 4 (175 V RMS). A sterile isotonic saline line was connected to the saline port of the device and flow set to 0.5 to 2 drops per second. After localization of the area to be treated, the device was placed on the tendon, perpendicular to its surface (Fig 5) and activated for 0.5 seconds with a pressure of approximately 5 to 8 g. Treatment was performed at 5-mm distance intervals on and around the symptomatic tendon area, creating a grid-like pattern. The fascia or tendon was perforated to a depth of several millimeters on each third or fourth application.

After treatment of the symptomatic area, the wound was irrigated with copious amounts of normal saline and closed with interrupted nylon suture. Local anesthetic was injected in the skin and subcutaneous tissue only. Standard wound dressing was then applied.

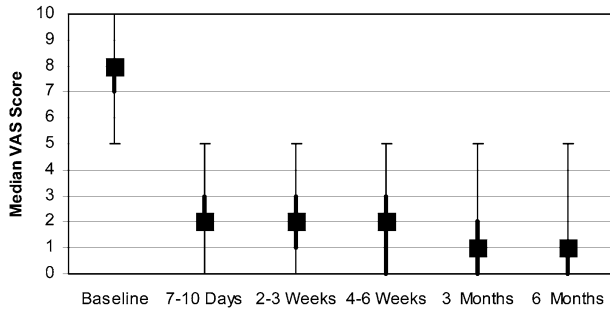


FIGURE 6. Graph representing reduction in visual analog scale scores, baseline to 6 months.

## Results

Twenty patients have been surgically treated, 3 patients in the Achilles group, 15 in the epicondyle group, and 2 in the patellar group. Patients were professional athletes, recreational athletes, or those with activity- or work-related disorders. No adverse event or complication has been observed to date. The mean duration of symptoms before surgery was 3.5 years, ranging from 6 months to 20 years. Patients failed an average of 4.5 conservative treatment modalities. Sixteen of 20 patients experienced noticeable reduction in pain as early as the first postoperative day and were able to separate the symptoms of tendinosis from the surgical wound pain. To date, follow-up treatment data is available for 20 patients at 7 to 10 days, 2 to 3 weeks, 4 to 6 weeks, 3 months, and 6 months.

Figure 6 shows preliminary results for self-reported pain. Before treatment, the average pain score was  $7.5 \pm 1.4$  (on a scale of 0-10). At 7 to 10 days, the average pain score was  $2.2 \pm 1.3$ . Postoperative pain score values were approximately 75% less (i.e., improved) over preoperative pain scores. The average

pain score at all postoperative time points was approximately 2 (median was similar, suggesting that pain reduction was stable through at least the first 6 months after the procedure). Nine of 20 (45%) patients reported VAS of 0 or 1 at 3 months and 16 of 20 (80%) of all subjects reported VAS of 0 or 1 at 6 months.

MRI changes at 6 months showed complete or near-complete resolution of tendinosis in 50% of patients. No significant change was noted in 38%, and 12% of patients had an increase in signal intensity (Fig 7).

## Discussion

All patients experience rapid relief of symptoms after the procedure. No complication was observed during the study procedures or at the required follow ups. Significant improvements were observed in all study patients during the first week of follow up, which appeared to remain constant over time. These preliminary results were very encouraging.

## Conclusion

Coblation is a new application of bipolar RF energy that creates a small, highly energized plasma at the tip of the active electrodes capable of breaking down molecular bonds of tissue. It appears there might be other biologic effects as well. Several studies have confirmed that Coblation-treated tissue exhibits a rapid and effective healing response. This could explain why patients treated in various surgical procedures using Coblation devices appear to recover significantly faster and with less pain than patients treated with conventional therapies.

In this article, three studies were discussed to support the use of Coblation to treat tendinosis.

The supraspinatus tendons from eight patients with rotator cuff tears were compared with six healthy

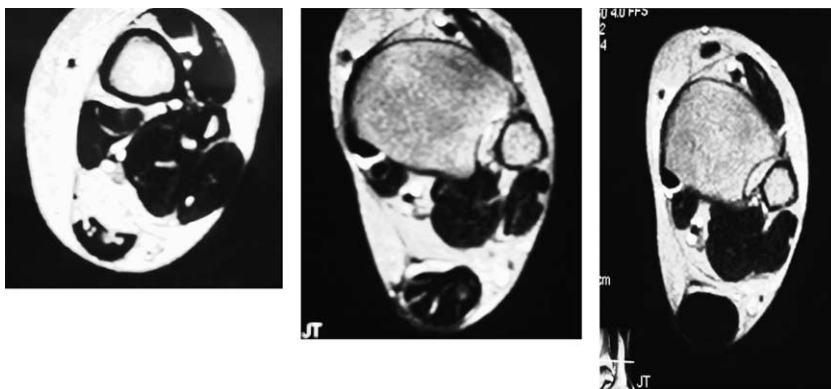


FIGURE 7. Magnetic resonance images of Achilles tendinosis (left, preoperative; middle, 6 weeks postoperative; right, 6 months postoperative) showing complete resolution.

tendons. The altered exhibited a lack of vascularity, expressed by a lower level of markers such as VEGF and  $\alpha_v$  integrin. These results confirm the work from Ahmed et al.<sup>15</sup> that tendon ruptures tend to occur in regions of hypovascularity.

A controlled study performed on 17 New Zealand white rabbits was conducted to study the effects on local vascularity and healing response of bipolar RF microdebridement in normal Achilles tendons. This study demonstrated that, when properly applied, Coblation devices have the ability to trigger a healing response that provides an increase in tissue vascularity as well as an increase in organized fibroblastic cells.

A novel small Coblation device applied for 0.5-second treatments every 5 mm on tendons diagnosed with tendinosis significantly improved pain symptoms over the short-term in a small group of patients. These results need to be confirmed with longer-term follow up and in a larger controlled study, both of which are being undertaken.

Treatments for tendinosis include activity modification, nonsteroidal anti-inflammatory administration, corticosteroid injections, bracing, physical therapy, surgical debridement, and extracorporeal shock wave therapy. This preliminary data has demonstrated both procedure and device safety. It has also documented short-term efficacy of the treatment of tendinosis with the Topaz bipolar RF microdebridement system. A larger prospective, multicenter controlled study will be conducted to confirm these positive results.

### EXTRACORPOREAL SHOCK WAVE THERAPY IN ORTHOPAEDIC SURGERY

A great deal of the information on ESWT in the subsequent paragraphs has come from Brian Day, MD, at the University of British Columbia, Vancouver, British Columbia, Canada. Acoustical extracorporeal shock waves have been used for the past 20 years. Chaussy and his colleagues introduced the first clinically successful device using shock wave for medical treatment in 1980.<sup>24</sup> In 1987, the Puigvert Group in Barcelona, Spain, used a variable energy lower-intensity electromagnetic lithotripter (Lithostar; Siemens Medical, Munich, Germany) to demonstrate that kidney stones could be successfully fragmented by low-energy shock waves. This approach eliminated the need for anesthesia.<sup>25</sup> These studies showed that shock waves had an analgesic effect, and treatment could be started at lower energy levels. Power settings could be increased with minimal patient discomfort and, in a stepwise fashion, oftentimes significantly

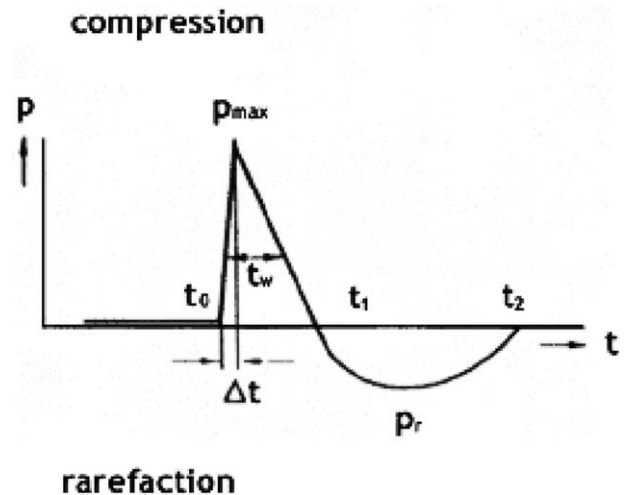


FIGURE 8. “The shock front” showing a large change in pressure amplitude.

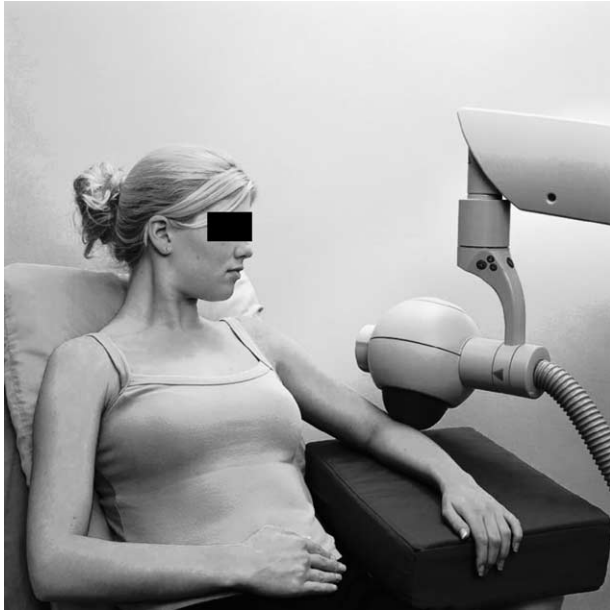above for those that previously required anesthesia. This was considered a “hyperstimulation analgesic effect” or a “TENS-like effect” of shock wave. This led to a rather widespread adoption of lower-energy, anesthesia-free lithotripsy for kidney stones. The first experimental treatment in animals was done in 1986, and the conclusion was that shock waves could affect the radiologic, biochemical, and histologic signs of simulated fracture healing.<sup>26,27</sup>

In 1988, the first human pseudarthrosis treatments were reported, and an important observation during that time was that patients who had treatment of their pseudarthrosis also reported pain relief.<sup>28</sup> In 1992, Dahmen reported the use of low-energy shock waves for tendinopathies and other soft tissue painful sites.<sup>29</sup> Wurtz was followed by Lowe (1993, 1995), Rumpe (1995, 1997), Heidelberg and Minz.<sup>30</sup> They were able to demonstrate that symptoms associated with tendinosis and other musculoskeletal conditions could be alleviated.

There have been multiple publications on its use for conditions such as lateral epicondylitis, plantar fasciitis, patellar tendonitis, and rotator cuff tendonitis over the past 3 to 4 years (Rompe JD, Decking J, Schoellner C, et al., personal communication, 1999).<sup>31-36</sup>

### Physics of Shock Waves

A shock wave can be described as a highly nonlinear and nonharmonic acoustic sound wave that is characterized by an extreme change in pressure amplitude, the so-called shock front (Fig 8). The energy is expressed in a bar or megapascals. The focal zone of



**FIGURE 9.** Application of extracorporeal shock wave therapy with a Siemens Sonorex office unit.

a shock wave is by definition “the volume within which the shock wave pressure is greater than 50% of the maximum pressure.” A common property of all shock waves is the cigar-shaped three-dimensional area of the focal zone with a pressure distribution broader in the axial direction than the lateral direction.<sup>37</sup> The devices that are presently available have very wide ranges of energy intensity. Generally they are grouped into either “high”-energy or “low”-energy classifications, and there could be some overlap in the delivery of these energy levels. The high-energy devices require a physician to be present to administer the anesthetic and treatment. These procedures are usually done in an ambulatory surgical unit or hospital. By contrast, lower-energy shock wave therapy is usually done in the office or clinic setting, and does not require anesthesia or an imaging device (Fig 9). The physician must be present, must prescribe the treatment, and then an ESWT technician can administer this. Regardless of the type, the parameters of the shock waves are similar in their ability to relieve pain and promote healing by physics and biologic effects and actions that are still not completely understood.

Tissue effects have been postulated to occur in four specific phases (Fig 10):

1. Physical phase: There are extracellular cavitations, ionized molecules, and increased mem-

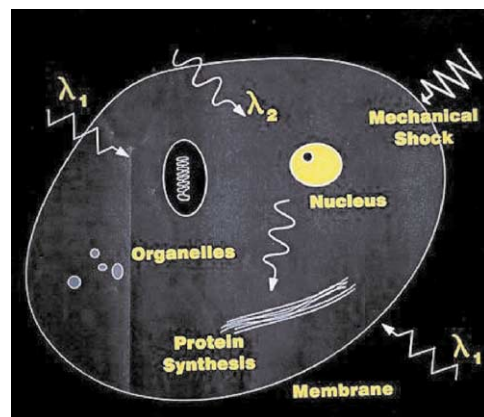
brane permeability as direct effects of shock waves.

2. Subsequent physical chemical phase: Diffusible radicals and reactions with biomolecules. (In both phases, mitochondrial lesions have been observed with electron microscopy.)
3. Chemical phase: Intracellular reactions from molecular changes.
4. Biologic phase: The observable result in exposed tissue when these changes persist.<sup>38</sup>

There are proposed hypotheses regarding the biologic effects in the areas as follows:

5. Shock wave changes the cell membrane of the nerve cells in the treated area, therefore no generator potentials can be built up in the nociceptor.
6. The shock waves cause chemical alterations and/or induced formation of chemical compounds, which reduce the effect of transmission of painful stimuli.
7. Hyperstimulation analgesia-shock waves stimulate nerves through a complicated pathway that inhibits pain sensation transmission.
8. Shock waves induce neovascularization. This results in increased blood supply to the treated area and promotes healing.<sup>39-41</sup>

There are multiple indications at this stage for the use of this technology, which include tendinosis of the rotator cuff, lateral epicondyle, patella, Achilles, as well as plantar fasciitis, trochanteric bursitis, metatarsal stress fractures, and tendinosis about the wrist. There are a number of investigational areas in which this technology is being used such as in avascular



**FIGURE 10.** Cellular reactions secondary to shock wave. (Courtesy of R. Jackson, M.D.)



necrosis, nonunions, and small joint arthrosis, as well as many others. The prerequisites for a patient to be considered for treatment with this ESWT include a small area of localized pain that is easily located by palpation. The patient should not have more than three areas of localized pain. There must be an anatomic correlation of the pain to the pathologic entity. One must also have a cooperative patient.

## Discussion

Conservative care of the wide variety of patients with tendinosis is well known to the orthopedist. Conservative care usually encompasses the use of NSAIDs. It has been estimated that there are approximately 16,500 NSAID-related deaths yearly in the United States, and serious toxicity "leading to hospitalization" from NSAID use occurs for an estimated 100,000 to 200,000 people per year. It is, therefore, not necessarily appropriate for NSAIDs to be considered as a benign or conservative treatment.

These painful overuse conditions are frequently unresponsive to conventional therapy. Patients are not able to work or pursue recreational activities. There is ample support in the literature for use of ESWT for these conditions, and with the current availability of this technology in the United States, it promises to be more commonly used. This procedure, when done in the office environment, is quite easy to administer, safe, and performed with minimal or no significant complications. There have been some reports of animal tendon injury with higher-energy flux densities ( $0.6 \text{ mJ/mm}^2$ ).<sup>16</sup> All treatments delivered by the low-energy device are at energy settings that result in energy flux densities of  $0.24 \text{ mJ/mm}^2$  or below.

## Rationale and Economic Advantages

Having these services available will help us recapture lost patients who are currently being treated by primary care physicians, chiropractors, and trainers. In many cases, we are viewed as surgeons rather than orthopedists who are capable of rendering both surgical and nonsurgical care. Many of these patients are self-treating and seek no medical advice from specialty-trained orthopedists.

We oftentimes underestimate the pain and disability that is associated with chronic tendinosis, and when these conditions are reversed or ameliorated, the patients are extremely grateful, which in turn leads to a great sense of satisfaction to the orthopedist. Many of these patients will present with their own diagnosis of tendinosis or tendonitis, and will have an underlying

entity that requires conventional surgery such as a rotator cuff tear.

For many orthopedists, this will allow them entry into the sports medicine arena, attracting a lot of young athletic and active individuals who are seeking relief from painful conditions that interfere with their ability to perform their selected sport. The actual time that it takes to render both the microinvasive surgical technique with Topaz as well as the ESWT is very short, they take up very little office and surgical time, and the follow-up is uncomplicated. The minimally invasive Topaz bipolar radiofrequency procedure (bRf) is done as an outpatient in approximately 15 to 20 minutes. It is extremely cost-effective, and the patients return to function and sports in a very short period of time. The office-based ESWT is done by a technician with a physician present in the office; again, this does not take much time. The average time from positioning to application of the shock wave until the patient leaves the room is approximately 15 minutes.

The economics of both of these entities are as follows. Topaz is billed as a tenotomy and every anatomic area that we generally treat has a CPT code for tenotomy, so preauthorization with the insurance company is usually quite easy. The procedure is actually a tenotomy and debridement; both of these are well accepted by the insurance industry. The usual charge for these procedures is approximately \$800 to \$1,200. With an efficient operating room staff, one can usually do at least two to three of these per hour.

ESWT is an office-based technology when one is using the low-voltage unit. It is technician-operated, but it is mandatory that the physician be present. The usual charge is \$600 to \$800 per treatment, and the recommended number of treatments is three. There is a CPT code, but is a "T" code (i.e., a tracking code). Approximately 30% of insurance companies are approving this technology today; however, that number appears to be increasing as the science is better accepted. Because the fee is of a moderate cost, a number of patients choose to pay cash, keeping the receipt for potential future reimbursement, and could receive a cash discount by paying ahead of time. Patients will occasionally elect surgery versus ESWT for financial reasons only. There is a cost associated with the machine, which varies from company to company, but in general there is a monthly lease plus a use fee. In the case of the Sonocur device, the monthly lease is approximately \$1600 to \$1,800 per month, with an application fee of \$115 to \$140 per treatment. This

usually leaves the physician with a 70% to 80% margin of profit.

If one chooses to market the device, there are a number of potential target audiences that appear to be quite interested in the technology. Letters and marketing material can be sent to workers' compensation carriers. This seems to be an effective strategy in that this is a very cost-effective treatment as well as having proven safety and efficacy. One might choose to send letters to your referring doctors and colleagues who will not have access to the office-based ESWT and are not surgeons, and therefore unable to do Topaz microdebridement. Developing a tendon treatment center with your hospital or surgery center is another option that allows increased visibility for your hospital campus as well as your surgery center. One can certainly use press releases, television, radio, or newspaper to reach the consumer. Community lectures have been considered effective for other orthopaedic problems and procedures. The greatest source of patients, however, will continue to be word of mouth from gratified patients.

You will only have a few years to capitalize on this opportunity. As the technology becomes more readily available, there will be little to differentiate your center from others. One only has to look at procedures such as total hip and knee replacement as well as anterior cruciate ligament (ACL) reconstruction. These were procedures in the past that went to subspecialists, and now many in the orthopaedic community perform these. This is the time to delineate yourself from the others and offer a service that is not only unique, but gratifying.

## REFERENCES

1. Stalder KR, Woloszko J, Grown IG, Smith CD. Repetitive plasma discharges in saline solutions. *Applied Physics Letters* 2001;79:4503-4505.
2. Stalder KR, Woloszko J, Grown IG, Smith CD. Repetitive plasma discharges in saline solutions. *Applied Physics Letters* 2001;79:4503-4505.
3. Woloszko J, Stalder KR, Brown IG. Plasma characteristics of Repetitively-pulsed electrical discharges in saline solutions used for surgical procedures. *IEEE Trans Plasma Sci* 2002;3:1376-1383.
4. Anpilov AM, Barkhudarov EM, Bark YB, et al. Electric discharge in water as a source of UV radiation, ozone and hydrogen peroxide. *J Phys D: Appl Phys* 2001;34:993-999.
5. Malik MA, Ghaffar A, Malik SA. Water purification by electrical discharges. *Plasma Sources Sci Technol* 2001;10:82-91.
6. Grekin RC, Tope WD, Yarborough JM, et al. Electrosurgical facial resurfacing: a prospective multicenter study of efficacy and safety. *Arch Dermatol* 2000;136:1309-1316.
7. Bortnick DP. Coblation: an emerging technology and new technique for soft-tissue surgery. *Plast Reconstr Surg* 2001;107:614-615.
8. Hall DJ, Littlefield PD, Holtel MR. Radiofrequency ablation versus electrocautery in tonsillectomy. *J Otolaryngol Head Neck Surg* 2001;125:211.
9. Lee KC, Altenau MM, Barnes DR, et al. Incidence of complications for subtotal ionized field ablation of the tonsils. *Otolaryngol Head Neck Surg* 2002;127:531-538.
10. Sharps LS, Isaac Z. Percutaneous disc decompression using Nucleoplasty. *Pain Physician* 2002;5:121-126.
11. Kantor B, McKenna CJ, Caccitolo JA, et al. Transmyocardial and percutaneous myocardial revascularization: current and future role in the treatment of coronary artery disease. *Mayo Clin Proc* 1999;74:585-592.
12. Kwon HM, Hong BK, Jang GJ, et al. Percutaneous transmyocardial revascularization induces angiogenesis: a histologic and 3-dimensional micro computed tomography study. *J Korean Med Sci* 1999;14:502-510.
13. Cook JL, Khan KM, Maffulli N, Purdam C. Overuse tendinosis, not tendonitis. *Physician Sports Med* 2000;28(6).
14. Kraushaar BS, Nirschl RP. Tendinosis of the elbow (tennis elbow). Clinical features and findings of histological immunohistochemical, and electron microscopy studies. *J Bone Joint Surg Am* 1999;81:259-278.
15. Alfredson H, Lorentzon R. Chronic Achilles tendinosis: recommendation for treatment and prevention. *Sports Med* 2000;29:135-146.
16. Ahmed IM, Lagopoulos M, McConnell P, Soames RW, Sefton GK. Blood supply of the Achilles tendon. *J Orthop Res* 1998;16:591-596.
17. Kraus-Hansen AE, Fackelman GE, Becker C, Williams RM, Pipers RS. Preliminary studies on the vascular anatomy of the equine superficial digital flexor tendon. *Equine Vet J* 1992;24:46-51.
18. Brooks PC, Clark RA, Cheresh DA. Requirement of vascular integrin  $\alpha_v\beta_3$  for angiogenesis. *Science* 1994;264:569-551.
19. Brooks PC, Stromblad S, Klemke R, Visscher D, Sarkar FH, Cherish DA. Anti-integrin  $\alpha_v\beta_3$  blocks human breast cancer growth and angiogenesis in human skin. *J Clin Invest* 1995;96:1815-1822.
20. Beck L, D'Amore PA. Vascular development: cellular and molecular regulation. *FASEB J* 1997;11:365-373.
21. Bussolino F, Mantovani A, Persico G. Molecular mechanisms of blood vessel formation. *Trends Biochem Sci* 1997;22:251-256.
22. Carmeliet P, Ferreira V, Breier G. Abnormal blood vessel development and lethality in embryos lacking a single VEGF allele. *Nature* 1996;280:435-439.
23. Ahmed IM, Lagopoulos M, McConnell P, Soames RW, Sefton GK. Blood supply of the Achilles tendon. *J Orthop Res* 1998;16:591-596.
24. Medlock VB, Amiel D, Harwood F, Ball S, Tasto JP. Cellular structural and angiogenic response to bipolar radiofrequency treatment of normal rabbit Achilles tendon. E-Poster presented at 21st AANA Meeting; Washington, DC; April 25-28, 2002.
25. Medlock VB, Amiel D, Harwood F, Ball S, Tasto JP. Rotator cuff tears: potential marker for angiogenesis. E-Poster presented at 21st AANA Meeting; Washington, DC; April 25-28, 2002.
26. Chaussy C, Brendel W, Schmiedt E. Extracorporeally induced destruction of kidney stones by shock waves. *Lancet* 1980;2:1265-1268.
27. Schild-Gutman J, Jordon WR, Weiland W. Lithostar: low pressure treatment of renal stones. *Siemens Electro-Media* 1990;58:33.
28. Haupt G, Haupt A, Gerety B, Chvapil M. Enhancement of fracture healing with extracorporeal shock waves. *J Urol* 1990;158:4.
29. Haupt G, Haupt A, Ekkernkamp A, Gerety B, Chvapil M. Influence of shock waves on fracture healing. *Urology* 1992;39:529-532.

30. Vlachanow VD, Michailow P. High energy shock waves in the treatment of delayed and non-union fractures. *Int Orthop* 1991; 15:181.
31. Dahmen GP, Meiss L, Nam VC, Franke R, Gonchars V. Extrakorporal stosswellentherapie (ESWT) im knochenanhen weichteilbereich and der schulter. *Erste Therapieergebnisse Ext Orthop* 1992;15:25.
32. Rompe JD. Efficient use of extracorporeal shock waves in tendinopathies. *Siemens Electro-Medical* 1997;65:20.
33. Chung B, Wiley JP. Extracorporeal shock wave therapy: a review. *Sports Med* 2002;32:851-865.
34. Maier M, Steinborn M, Schmitz C, et al. Extracorporeal shock wave therapy for chronic lateral tennis elbow—prediction of outcome by imaging. *Arch Orthop Trauma Surg* 2001;121: 379-384.
35. Schmitt J, Tosch A, Hunerkopf M, Haake M. Extracorporeal shock wave therapy (ESWT) as therapeutic option in supraspinatus tendon syndrome? One year results of a placebo controlled study. [German]. *Orthopade* 2002;31:265-657.
36. Peers KHE, Lysens RJJ, Brys P, Bellmans J. Cross-sectional outcome analysis of athletes with chronic patellar tendinopathy treated surgically and by extracorporeal shock wave therapy. *Clin J Sports Med* 2003;13:79-83.
37. Rompe JD, Decking J, Schoelner C, Nafe B. Shock wave application for chronic plantar fasciitis in running athletes: a prospective, randomized, placebo-controlled trial. *Am J Sports Med* 2003;31:268-275.
38. Petrone FA, Lefton CS, Romness DW, McCall BR, Covall DJ, Boatright JR. Evaluation of extracorporeal shock wave therapy for chronic lateral epicondylitis. Presented at the Annual Meeting of the American Academy of Orthopaedic Surgeons, Dallas, TX, February 13-17, 2002.
39. Mobley TB, Myers DA, Grine WB, Jenkins J, Jordan WR. Low energy lithotripsy with the Lithostar: treatment results with 19,962 renal and ureteral stones. *J Urol* 1993;149: 1419-1424.
40. Haupt G. Use of extracorporeal shock waves in the treatment of pseudo-arthritis, tendinopathy and other orthopaedic diseases. *J Urol* 1997;158:4.
41. Haupt G. Use of extracorporeal shock waves in the treatment of pseudo-arthritis, tendinopathy and other orthopaedic diseases. *J Urol* 1997;158:4.