

# A biomechanical evaluation of three surgical techniques for subscapularis repair

Gregory R. Van den Berghe, MD, Bao Nguyen, BS, Shantanu Patil, MD, Darryl D. D'Lima, MD, Andrew Mahar, MS, Robert Pedowitz, MD, PhD, and Heinz R. Hoenecke, MD, La Jolla, CA

*This study was designed to determine which subscapularis repair method performs best under fatigue loading. Fresh-frozen human cadaveric shoulders were used. A standard circumferential release was performed, including a rotator interval release and separation of the subscapularis from the anterior and inferior capsules. One of 3 methods was used to repair the subscapularis tendon: tendon-to-tendon, tendon-to-bone, or bone-to-bone using a buttress plate. The shoulder was mounted on a fatigue-testing machine, and the medial end of the subscapularis tendon was attached to a soft-tissue clamp. We initially tested each specimen for fatigue at 150 N for 500 cycles, then at 300 N for 2500 cycles. The failure rate of bone-to-bone and tendon-to-tendon repairs was significantly better than that of the tendon-to-bone repair. The bone-to-bone repair exhibited the best combination of repair strength and restoration of subscapularis length. (J Shoulder Elbow Surg 2008;17:156-161.)*

**T**otal shoulder arthroplasty (TSA) has proven to be a successful procedure with good long-term results.<sup>4,5,12</sup> Outcomes based on pain relief and function have shown success rates to be greater than 90%.<sup>4,5</sup> Despite predictable results, various complications after TSA have been reported,<sup>14</sup> including the loss of subscapularis function.<sup>12</sup> The commonly used deltopectoral approach for TSA involves detachment and repair of the subscapularis tendon. A meticulous repair of the subscapularis tendon is essential for postoperative shoulder function. The failure of this repair can lead to subscapularis muscle deficiency manifesting as pain, weakness, or anterior instability. The reported incidence of reduced postoperative subscapularis function is as high as 18% to 67%.<sup>5,11,12,14</sup>

Loss of function can be caused by shortening of the subscapularis, elongation, rupture of the repair, denervation, or overaggressive rehabilitation. Shortening of the subscapularis can restrict external rotation. On the other hand, excessive lengthening may result in weakness during activities involving the subscapularis, such as carrying large objects or even tucking in one's shirt. Careful examination of the subscapularis postoperatively can reveal weakness with belly-press or lift-off test.<sup>12</sup> One centimeter of tendon shortening can result in loss of 20° of rotation.<sup>10</sup>

The 3 possible methods of takedown and repair of the tendon are (1) transection of the tendon and end-to-end suture repair, (2) subperiosteal release of the tendon and repair to drill holes at the osteotomy site, (3) or lesser tuberosity osteotomy and replacement using transosseous sutures tied over a plate on the lateral humerus. Each of the 3 methods of repair has individual characteristics with respect to strength of repair versus lengthening or shortening of the tendon. Proponents of the bone-to-bone repair technique report consistent bone-to-bone healing and good postoperative subscapularis function.<sup>7</sup>

Each of these repair techniques has potential advantages. However, to our knowledge, a comparison of the strength of each repair technique and potential for change in net subscapularis tendon length has not been reported. We designed a cadaveric study to measure the fatigue strength of each type of repair and to establish the relative lengthening or shortening of the subscapularis tendon. The goal of the study was to determine the optimal repair method with respect to tendon length and strength of repair.

## MATERIALS AND METHODS

The study used 19 fresh-frozen human cadaveric shoulders. Gender distribution was 10 men and 9 women, and their mean age was 80 years (range, 71–89 years). Inclusion criterion was age older than 65 years. Exclusion criteria were the presence of glenohumeral pathology, such as anatomic deformities, evidence of previous fracture of the glenoid or humerus with malunion, or any evidence of surgery involving the glenohumeral joint, the anterior capsule, or subscapularis muscle.

Shoulders were randomly assigned to 1 of 3 repair groups: group 1, tendon-to-tendon; group 2, tendon-to-bone; and

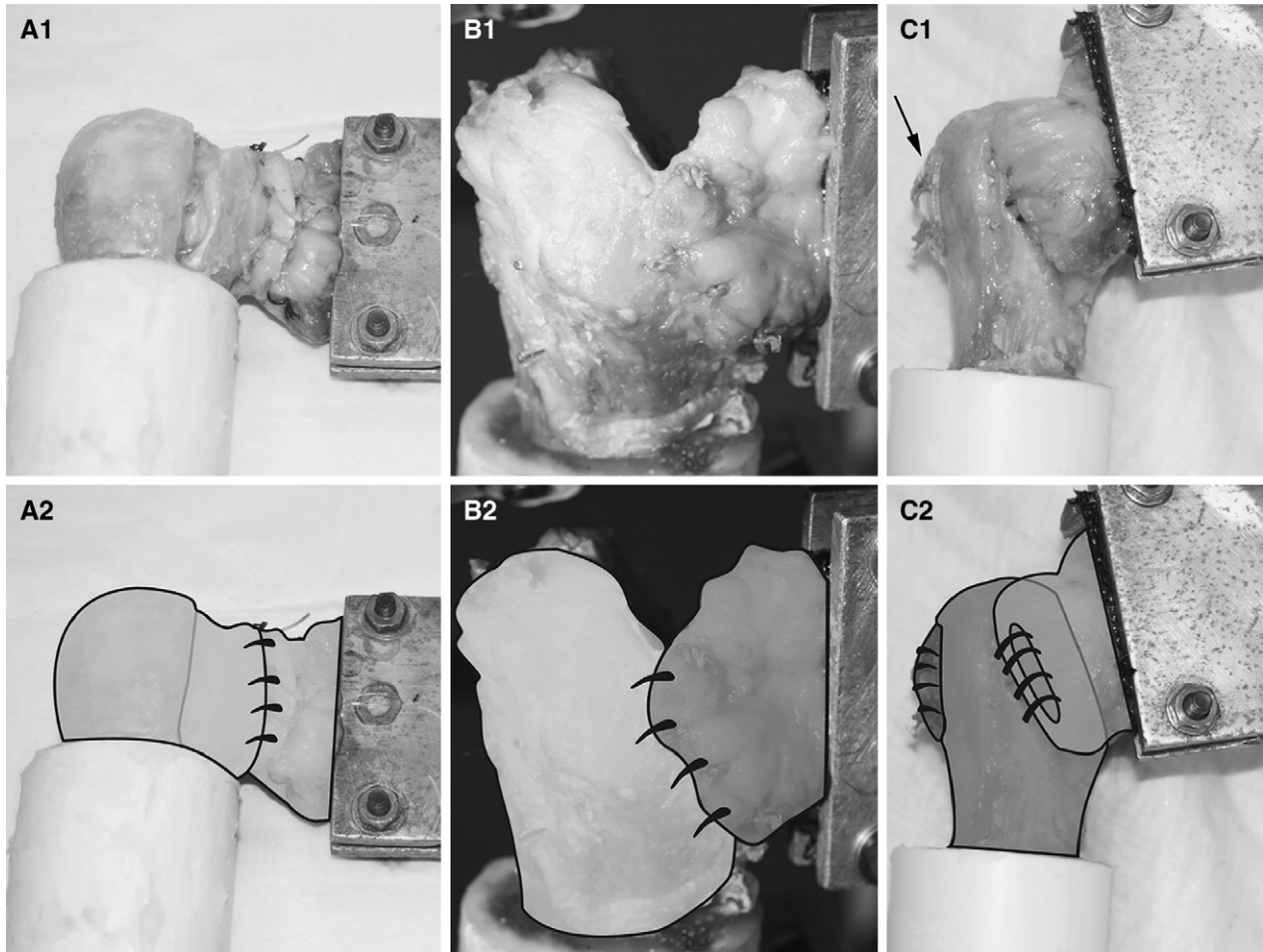
From Shiley Center for Orthopaedic Research and Education at Scripps Clinic.

Reprint requests: Heinz R. Hoenecke, MD, c/o Judy A. Blake, Shiley Center for Orthopaedic Research and Education at Scripps Clinic, 11025 N Torrey Pines Rd, Ste 140, La Jolla, CA 92037 (E-mail: [bhoeneck@san.rr.com](mailto:bhoeneck@san.rr.com); cc: [Blake.Judy@scrippshealth.org](mailto:Blake.Judy@scrippshealth.org)).

Copyright © 2008 by Journal of Shoulder and Elbow Surgery Board of Trustees.

1058-2746/2008/\$34.00

doi:10.1016/j.jse.2007.04.016



**Figure 1** Cadaver humeri were dissected leaving the subscapularis attachment intact. The humeral head was osteotomized as for a routine shoulder arthroplasty. The subscapularis tendon attachment was divided and was repaired using 3 different techniques (see Methods section for details). **A**, Tendon-to-tendon repair. **B**, Tendon-to-bone repair. **C**, Bone-to-bone repair (arrow points to buttress plate). **Panel 1**, Photographs of the procedure. **Panel 2**, Line diagrams showing the repair technique.

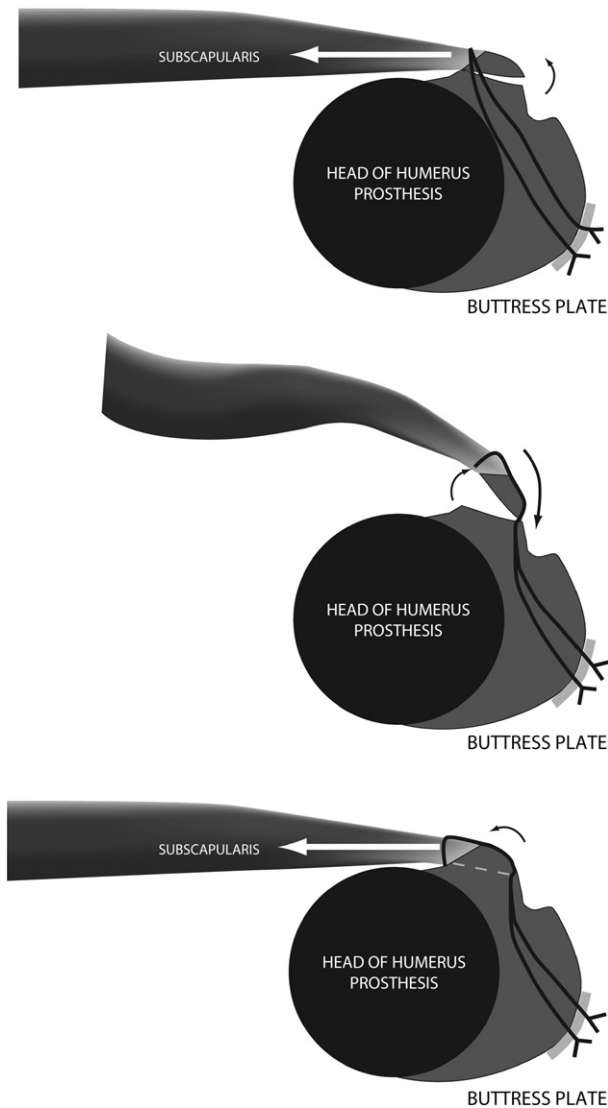
group 3, bone-to-bone. All shoulders were initially prepared by removing the skin and the deltoid muscle to expose the subscapularis muscle. The subscapularis tendon was released and was repaired as described below for the 3 repair types. A standard circumferential release was performed in all shoulders, including a rotator interval release and separation of the subscapularis from the anterior and inferior capsule.

Group 1 consisted of 6 shoulders (3 men and 3 women; mean age, 79 years; range, 71–88 years). The subscapularis tendon was dissected free from the capsule and cut 1 cm medial to the lesser tuberosity. Four No. 2 FiberWire (Arthrex Inc, Naples, Florida) sutures were placed in a horizontal mattress configuration 5 mm from each cut end and were used to imbricate the tendon (Figure 1, A).

Group 2 consisted of 6 shoulders (3 men and 3 women; mean age, 82 years; range 77–89 years). The subscapularis was released subperiosteally from the lesser tuberosity. A tendon-to-bone repair was performed using drill holes made 5 to 7 mm from the edge of the osteotomy (at the ana-

tomotic neck). Sutures of No. 2 FiberWire were passed into the drill holes and through the osteotomy and were secured with a horizontal mattress configuration through the tendon (Figure 1, B).

Group 3 consisted of 7 shoulders (4 men and 3 women; mean age, 77 years; range, 71–85 years). Group 3 shoulders were prepared using a previously described lesser tuberosity osteotomy and repair technique.<sup>6</sup> A flexible thin osteotome was used to remove the lesser tuberosity, resulting in a bony fragment that was about 30 to 40 mm long, 5 to 8 mm wide, and 5 to 8 mm thick. Sutures were passed transosseously through the proximal humerus using a bone tunnel drilling system (Curtek, Arthrotek, Warsaw, IN). Sutures of No. 2 FiberWire were placed through the tendon in a horizontal mattress, passed over the bone block, and then through the drill holes to be tied over a buttress plate (Lacto-Sorb RBC plate, Arthrotek) in a “back-pack” fashion (Figure 1, C). This technique created a tension-band effect that kept the lesser tuberosity fragment apposed against the pull of the subscapularis (Figure 2).



**Figure 2 A**, Diagram illustrates the tendency for the lesser tuberosity fragment to open laterally if a simple mattress suture is used for bone-to-bone repair. **B**, The lesser tuberosity fragment initially rotated externally in the cadavers (because of the lax subscapularis) and caused in initial "shortening." **C**, In the presence of subscapularis tension, the lesser tuberosity fragment was brought into compression and the tendon returned to preosteotomy length. The "back-pack" configuration of the sutures resulted in a "tension band" intended to create a compression rather than distraction at the repair site.<sup>6</sup>

The length of the tendon was measured before and immediately after repair at the upper, middle, and lower portions of the subscapularis. This was done by measuring from a marking suture placed at the musculotendinous junction to a fixed point on the humerus (pins placed in the bicipital groove). A digital caliper was used for measurements with a repeatability of  $\pm 0.8$  mm.

After the repair, the medial end of the subscapularis tendon was transected from the muscle belly, sutured to a nylon

strap, and attached to a soft-tissue clamp. The humerus was then cemented in a custom fixture and was mounted on a uniaxial servohydraulic testing machine (Instron-851, Instron, Canton, MA). The soft-tissue clamp was oriented to provide a linear force on the subscapularis tendon for cyclic loading, which simulated the arm at the side in neutral rotation with the subscapularis initiating internal rotation. Slippage of the clamp was not independently monitored; however, these clamps have been validated in a previous study involving the supraspinatus tendon.<sup>15</sup> This testing setup is similar to previous cyclic loading experiments involving the supraspinatus tendon and suture anchors.<sup>3,15</sup>

A standardized testing method for cyclic loading of the subscapularis tendon has not been developed to our knowledge. Many methods and studies have been devoted to the supraspinatus tendon and suture anchors placed within the greater tuberosity.<sup>1-3,15,16</sup> In developing our testing protocol, a specimen was tested to determine the load versus elongation curve of an intact tendon. An additional 3 specimens were then loaded to failure to determine the tensile strength of the subscapularis tendon and location of failure. Our pilot study measuring pullout strength revealed that the tendon-to-bone interface in normal cadaver shoulders failed at approximately 700 N, with the failure occurring at the tendon-to-bone interface in all 3 specimens. Halder et al<sup>8</sup> demonstrated that the superior and midsuperior portions of the subscapularis tendon were significantly stronger and stiffer than the midinferior and inferior portions with the hanging arm position. Regional variations of the superior and inferior tendon qualities, as well as the change in strains with different arm positions, reinforced the fact that the inferior aspect of the tendon consistently failed first.

In pilot testing, tendon-to-tendon repairs using FiberWire suture failed at about 450 N (single-cycle testing to failure). Hughes et al<sup>9</sup> predicted subscapularis forces of up to 283 N in a biomechanical model of the shoulder during abduction and adduction tasks. A simple free-body analysis of the glenohumeral joint and subscapularis forces during a 20- to 40-N belly-press was calculated. The shoulder was represented by a ball-and-socket joint. The ratio of the subscapularis insertion moment arm to the moment arm of the forearm was estimated to be 1:10. The contribution of other muscles was ignored. Subscapularis forces were calculated to be 200 N for a 20-N belly-press and 400 N for a 40-N belly-press. Two loads were chosen for the fatigue test: 33% (150 N) and 67% (300 N) of the maximum strength of a tendon-to-tendon repair. These were considered to be clinically relevant by the aforementioned theoretic assumptions, experimental data, and published reports.

After a preload of 10 N was applied, each specimen was initially tested at 150 N for 500 cycles, then at 300 N for 1500 cycles (sinusoidal waveform, 1-Hz frequency). The extent to which the repair failed through the tendon, suture, or bone was observed and measured. If a failure did not occur by 3000 cycles, we concluded that failure would be unlikely<sup>2</sup> and stopped loading the specimen. Failure was defined as complete separation of the repair interface. In the absence of complete separation, a lengthening of the tendon greater than 5 mm at the end of the 3000 cycles denoted partial failure such as might occur with sutures cutting through bone without separation of the interface or subsidence of the buttress plate.

### Statistical analysis

The Student *t* test was used to test for significant differences in shortening of the tendon after repair. A sample size of 6 has a power of 80% or greater to detect a difference of 5 mm or more at  $\alpha = 0.05$ . The Fisher exact test was used to determine differences in failure rates among the groups. It was determined that a sample size of 6 has a power of 80% or greater to detect a difference of 4 specimens or more at  $\alpha = 0.05$ . A value of  $P < .05$  was used to denote statistical significance.

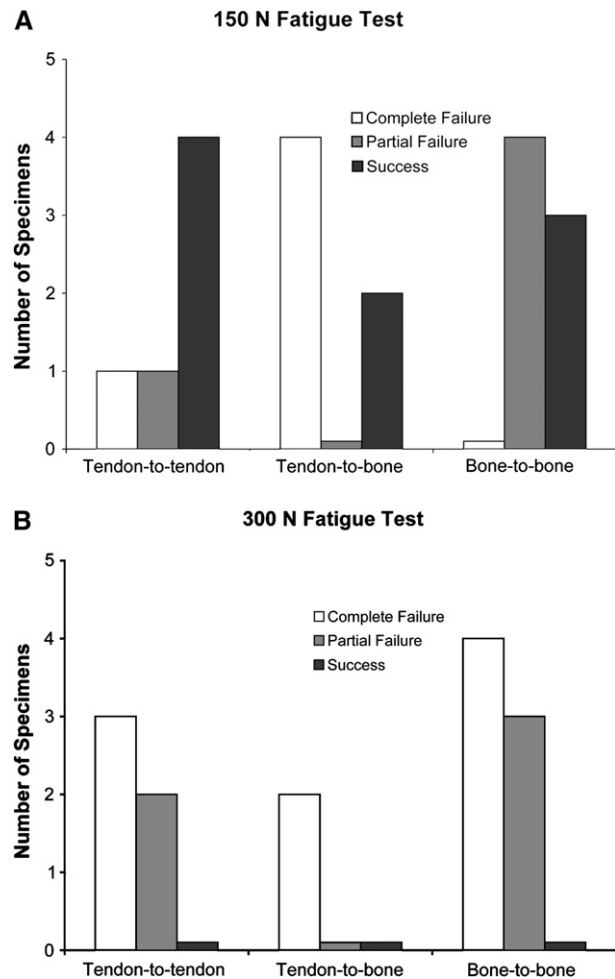
## RESULTS

In group 1, the tendon-to-tendon repair resulted in a mean shortening of the tendon of  $5.3 \pm 1.2$  mm, reflecting our surgical imbrication technique. In group 2 (tendon-to-bone), there was a mean lengthening of  $2.6 \pm 3.7$  mm. Group 3 (bone-to-bone) demonstrated a mean shortening of  $4.4 \pm 3.2$  mm. The method of suture placement in group 3 caused an external rotation of the bone fragment (Figure 2), which contributed to initial shortening. This rotation was probably an artifact due to absent subscapularis tension in the cadaver shoulder, because this has neither been reported in clinical studies nor observed in our surgical experience. The rotation of the bone fragment corrected itself with good bone-to-bone apposition and restoration of subscapularis tendon length during the initial 10-N preload. The change in length of the tendon after repair was statistically significant between groups 1 and 2 (Student *t* test,  $P = .02$ ).

The results of the sequential fatigue tests are summarized in Figure 3. Group 1 had 1 complete separation and 1 partial failure (5-mm gap formation) at 150 N. The complete separation did not occur at the repair site but was the result of avulsion of the tendon insertion at the humerus. Two more specimens failed completely at the first cycle at less than 300 N. Of the remaining 2 specimens, 1 failed completely at cycle 980, whereas the other had failed partially at the end of the 1500 cycles.

In group 2, 67% (4 of 6) of the specimens failed completely during the 150-N testing phase. All of the failures occurred because the sutures cut through the humeral bone at the site of the osteotomy. The remaining 2 specimens failed completely during the 300-N testing phase at cycles 5 and 320, respectively.

In group 3, no complete failures occurred during the 150-N test phase, but 3 specimens (42%) failed partially. In 1 case, the buttress plate deformed and sank into the lateral cortex. In 2 specimens, the suture partially cut through the bone. During the 300-N test phase, the partial failures progressed to complete failure. Of the 4 repairs that survived the 150-N test phase, 2 specimens failed at the suture-tendon interface after 13 and 16 cycles, respectively. The remain-



**Figure 3 A,** The number of specimens in each failure category is shown at the end of the 150-N fatigue test. **B,** Results for the 300-N fatigue test. (Note: A small value has been added to failure groups containing 0 specimens for visibility of the column.)

ing 2 specimens failed partially because the sutures began to cut through the bone.

The rate of complete failure at the end of the 150-N test phase was significantly higher in the tendon-to-bone group (group 2) compared with the bone-to-bone group (group 3; Fisher exact test,  $P = .02$ ). No significant differences were noted in the rates of complete failure between groups 1 and 2 ( $P = .24$ ) or between groups 1 and 3 ( $P = .46$ ). No significant differences were noted in partial or complete failure rates at the end of the 300-N test phase.

## DISCUSSION

This cadaveric study evaluated the initial changes in length and the mode of fatigue failure of the tendon after 3 repair methods that could affect range of motion and strength:



- The tendon-to-tendon repair group (group 1) demonstrated the most shortening (5.3 mm  $\pm$  1.2 mm) after subscapularis tendon repair, which could potentially result in a loss of external rotation. One centimeter of shortening may cause loss of 20° of external rotation.<sup>10</sup> However, the imbrication technique that was used in this experiment differs from the usual clinical repair technique that does not shorten the tendon.
- The tendon-to-bone repair group (group 2) resulted in lengthening of the tendon. Lengthening might be desirable in the case of a contracted capsule and subscapularis muscle but might reduce the strength the subscapularis muscle.
- The bone-to-bone repair (group 3) did cause an initial shortening (4.4 mm  $\pm$  3.2 mm) due to external rotation of the bone fragment during the placement of the sutures, which corrected during the initial 10-N preload.

In this study, we attempted to replace the tuberosity fragment to its anatomic site, but it is possible to place it more medially or laterally if shortening or elongation of the tendon is desired.

Miller et al<sup>12</sup> reported a trend (not statistically significant) toward better clinical subscapularis function when the tendon repair was reinforced with bone tunnel sutures at the anatomic neck of the humerus. In our in vitro study, however, group 2 failed at the lower load (150 N), with the sutures cutting out of the bone at the osteotomy site resulting in a complete failure of the repair rather than a partial failure, which was more common in the groups 1 and 3 specimens. Suture selection can have an effect on this type of failure. We chose No. 2 FiberWire, which is what we use clinically. A thicker suture might be more resistant to this type of failure. We could not determine if the relative elongation of the tendon, compared with the other repair techniques, would result in lower loads during the rehabilitation process and thereby decrease the incidence of complete failure in the clinical setting.

The rigidity of the repair technique for group 3 might be increased by using a metal buttress plate, as originally described by Gerber et al.<sup>7</sup> The strength of the bone-to-bone repair method may be significantly enhanced by passing the sutures around the stem of the implant instead of using a plate laterally.<sup>13</sup>

One potential limitation of the study was that the shoulders were not matched. Therefore, differences in bone or tendon quality may have biased the results. The repair techniques used in our study may not reflect the techniques used by other shoulder arthroplasty surgeons. As noted, tendon-to-tendon repair is possible without imbrication, which shortens the tendon. A straight linear tensile force was applied to simulate a contracting subscapularis muscle against resistance.

In vivo, the subscapularis tendon may be subjected to multi-axial forces according to shoulder position and muscle contraction status. Finally, the cadaver model only simulated the immediate postoperative period. We could not evaluate any potential biologic differences between bone-to-bone or tendon-to-tendon healing that may occur in vivo.

Bone-to-bone repair of the subscapularis after shoulder arthroplasty was significantly stronger than the tendon-to-bone repair and may offer the theoretic biologic advantage of bone-to-bone healing. Tendon-to-tendon repair demonstrated comparable strengths of repair with the other two methods used in our study. Tendon-to-bone repair at the osteotomy site allowed for lengthening of the repaired tendon but failed at lower loads than repair by other methods. The failure appeared to be related to the strength of the bone at the site of osteotomy; therefore, the bone at the osteotomy should be carefully evaluated during the repair when this method is used.

## REFERENCES

1. Barber FA, Herbert MA, Richards DP. Sutures and suture anchors: update 2003. *Arthroscopy* 2003;19:985-90.
2. Burkhart SS, Diaz Pagan JL, Wirth MA, Athanasiou KA. Cyclic loading of anchor-based rotator cuff repairs: confirmation of the tension overload phenomenon and comparison of suture anchor fixation with transosseous fixation. *Arthroscopy* 1997;13:720-4.
3. Bynum CK, Lee S, Mahar A, Tasto J, Pedowitz RA. Failure mode of suture anchors as a function of insertion depth. Proceedings, Arthroscopic Association of North America (AANA) 70th Annual Meeting, Phoenix, Arizona, 2003.
4. Cofield RH, Edgerton BC. Total shoulder arthroplasty: complications and revision surgery. *Instr Course Lect* 1990;39:449-62.
5. Dugas JR, Campbell DA, Warren RF, Robie BH, Millett PJ. Anatomy and dimensions of rotator cuff insertions. *J Shoulder Elbow Surg* 2002;11:498-503.
6. Gerber C, Pennington SD, Yian EH, Pfirrmann CA, Werner CM, Zumstein MA. Lesser tuberosity osteotomy for total shoulder arthroplasty. Surgical technique. *J Bone Joint Surg Am* 2006;88(Suppl 1 Pt 2):170-7.
7. Gerber C, Yian EH, Pfirrmann CA, Zumstein MA, Werner CM. Subscapularis muscle function and structure after total shoulder replacement with lesser tuberosity osteotomy and repair. *J Bone Joint Surg Am* 2005;87:1739-45.
8. Halder A, Zobitz ME, Schultz E, An KN. Structural properties of the subscapularis tendon. *J Orthop Res* 2000;18:829-34.
9. Hughes RE, An KN. Force analysis of rotator cuff muscles. *Clin Orthop Relat Res* 1996;330:75-83.
10. Matsen FA, Rockwood CA. Anterior gleno-humeral instability. In: Rockwood CA, Matsen FA, editors. *The Shoulder*. Philadelphia: Saunders; 1990. p. 526-622.
11. Miller BS, Joseph TA, Noonan TJ, Horan MP, Hawkins RJ. Rupture of the subscapularis tendon after shoulder arthroplasty: diagnosis, treatment, and outcome. Proceedings 2003 AAOS Annual Meeting 2003;451.
12. Miller SL, Hazrati Y, Klepps S, Chiang A, Flatow EL. Loss of subscapularis function after total shoulder replacement: A seldom recognized problem. *J Shoulder Elbow Surg* 2003;12:29-34.
13. Millett PJ, Ponce B, Ahluwalia R, Mazzocca AD, Santagelo SA, Warner JJ. Subscapularis dysfunction after total shoulder

- arthroplasty: a biomechanical and clinical evaluation of a novel lesser tuberosity osteotomy repair technique. Proceedings 2005 AAOS Annual Meeting 2005;530.
14. Moeckel BH, Alichek DW, Warren RF, Wickiewicz TL, Dines DM. Instability of the shoulder after arthroplasty. *J Bone Joint Surg Am* 1993;75A:492-7.
  15. Petit CJ, Boswell R, Mahar A, Tasto J, Pedowitz RA. Biomechanical evaluation of a new technique for rotator cuff repair. *Am J Sports Med* 2003;31:849-53.
  16. Waltrip RL, Zheng N, Dugas JR, Andrews JR. Rotator cuff repair. A biomechanical comparison of three techniques. *Am J Sports Med* 2003;31:493-7.