

# Optimizing glenoid component position using three-dimensional computed tomography reconstruction

Heinz R. Hoenecke Jr., MD,<sup>a</sup> Juan C. Hermida, MD,<sup>b</sup> Nicholas Dembitsky, BS,<sup>b</sup> Shantanu Patil, MD,<sup>b</sup> and Darryl D. D'Lima, MD, PhD,<sup>b</sup> La Jolla, CA

*Glenoid implant design and alignment are critical to the success of shoulder arthroplasty. Computer-aided design models of 3 glenoid implant designs (keel, standard pegs, and modified pegs) were virtually implanted into 3-dimensional computed tomography-reconstructed models of 40 normal scapulae. The incidence of perforation on 3-dimensional computed tomography preoperative templating varied from 8% to 18% for the 3 models. Malalignment of the implants in retroversion was better tolerated than anteversion and varied with implant design. Tolerance for medialization of the implant to correct for glenoid wear was limited (range, 0°-18°) and varied with implant design. The modified peg design had the lowest incidence of perforation, the greatest tolerance for malalignment, and the ability to correct for glenoid wear effects. These results emphasize the need for accurate preoperative templating and for developing alignment guides or surgical navigation tools for shoulder arthroplasty and may be used to improve implant fixation designs. (J Shoulder Elbow Surg 2008;17:637-641.)*

**S**houlder arthroplasty has been shown to have fewer early postoperative complications than either hip or knee arthroplasty.<sup>3</sup> On the other hand, a review of 40 studies (3584 patients) revealed a revision rate of 8%.<sup>12</sup> Loosening of the glenoid and humeral components is the most common complication, accounting for up to 39% of all reported complications.<sup>1</sup> The other major complications are glenohumeral instability, glenoid fracture, and overstuffing. All of these complications may be directly related to implant design and surgical alignment of components.

Complicating the placement of the glenoid implant is the size of the articular surface, the small volume of bone stock available for implant fixation, and the distorted anatomy resulting from the underlying arthritis. Appropriate version of the glenoid component is extremely important. Retroversion results in posterior translation of the humeral head and loading of the posterior portion of the glenoid, and anteversion results in loading of the anterior part of the glenoid.<sup>10</sup> Finite-element analysis has shown that version can affect cement mantle stresses.<sup>6</sup> In addition, inappropriate version can result in glenohumeral instability, subcoracoid or subacromial impingement, excessive implant wear, and aseptic loosening. Even if the appropriate glenoid version can be measured on preoperative computed tomography (CT) scans, current surgical techniques make it difficult to orient the glenoid implant at precisely the desired version, and surgical error can result in a suboptimal position with increased potential for perforation.

Retroversion of the glenoid is a common abnormality resulting from excessive wear in patients with arthritis of the shoulder. Eccentric reaming is often recommended to correct version abnormalities. However, eccentric reaming results in medialization of the implant, limiting the amount of version correction possible.

Current glenoid prosthetic designs are typically cemented. Pressurization of the cement can aid in interdigitation with the cancellous bone of the glenoid and enhance the implant-cement-bone interface.<sup>7</sup> Intraoperative perforation of the glenoid vault is a complication that has not received much attention.<sup>5</sup> However, perforation of the vault can prevent adequate cement pressurization. The potential for perforation is linked to implant design and implant position. The objectives of this study were, therefore, to determine the potential for implant perforation, to determine the accuracy required of the surgical technique with respect to anteversion and retroversion, and to determine the ability to correct wear deformities with eccentric reaming in 3 representative implant designs.

## MATERIALS AND METHODS

### *Three-dimensional CT-reconstructed models*

We obtained CT scans of 40 cadaveric shoulders that had no anatomic deformities or significant arthritic changes.

From the <sup>a</sup>Division of Orthopaedic Surgery and <sup>b</sup>Shiley Center for Orthopaedic Research and Education at Scripps Clinic.


This research project was funded by Scripps Health Foundation philanthropic funds.

Reprint requests: Heinz R. Hoenecke Jr., MD, Division of Orthopaedic Surgery, Scripps Clinic, 11025 N Torrey Pines Rd, Suite 140, La Jolla, CA 92037 (E-mail: [bhoeneck@san.rr.com](mailto:bhoeneck@san.rr.com)).

Copyright © 2008 by Journal of Shoulder and Elbow Surgery Board of Trustees.

1058-2746/2008/\$34.00

doi:10.1016/j.jse.2007.11.021



**Figure 1** Three computer-aided design models were constructed based on mean measurements made from commercially available designs to reproduce the fixation keel or pegs. The same dimensions of the fixation geometry (pegs or keel) were used in all 3 designs. **A**, The keeled design had a single central keel. **B**, The standard pegged design had 4 fixation pegs. **C**, The modified pegged design was constructed with pegs that had a 10% smaller diameter, were closer together, and had a shorter central peg.

CT scan images were segmented and converted to surface models of the scapula by use of a commercially available program (MIMICS; Materialise, Leuven, Belgium). The scapulae ranged from 21.2 to 36.7 mm in glenoid height, 15.4 to 27.9 mm in glenoid width, and 86.3 to 115.5 mm in length of the scapular axis (from the center of the glenoid to the tip of the scapular spine).

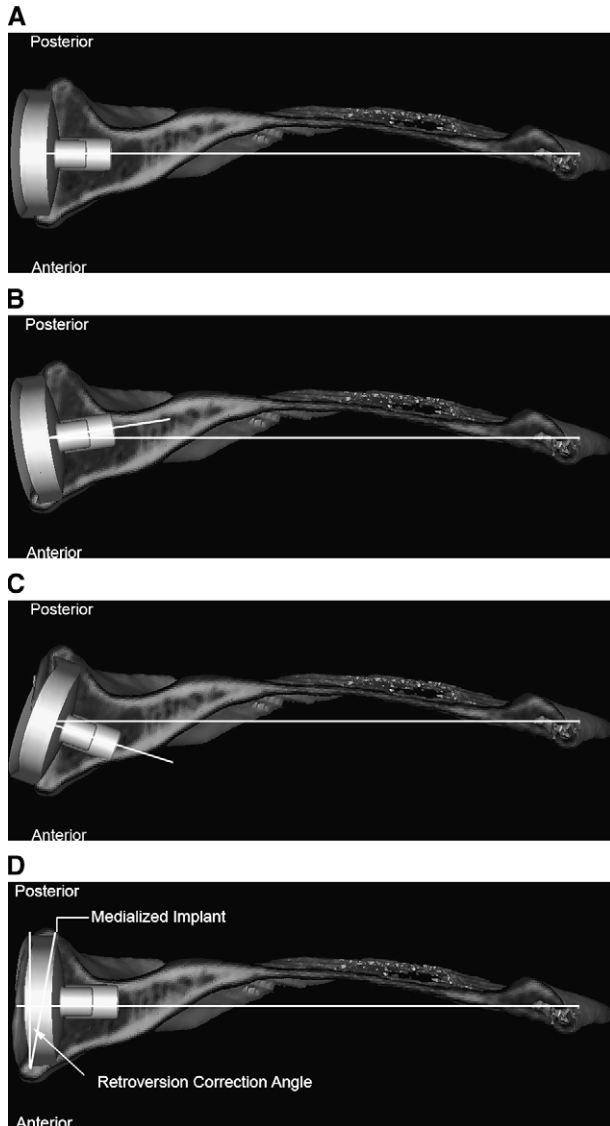
#### *Measurement of glenoid version*

Glenoid version was measured on the 3-dimensional (3D) CT-reconstructed models at the level of the center of the glenoid relative to the scapular axis (the line joining the tip of the scapular spine and the center of the glenoid.<sup>4</sup>)

#### *Glenoid implant design*

Most current-generation glenoid implants are fixed to the scapula with keels, pegs, or screws. To determine

the relative benefits of bone fixation and potential for perforation of these designs, 3 computer-aided design models were constructed to reproduce the fixation keel or pegs present in commercially available implant designs (Figure 1). The keeled design had a single central keel, and the standard pegged design had 4 fixation pegs, which are intended to distribute stresses at the bone-implant interface and to provide resistance in shear and torque.<sup>11</sup> Because there is potential for glenoid perforation during implantation, a modified pegged design was constructed with pegs that had a 10% smaller diameter, were closer together, and had a shorter central peg (Figure 1, C). The same articular surface geometry was used in all 3 designs. The most common implant design used clinically at our institution comes in several articular sizes, but the fixation geometry (including dimensions) is the same among sizes. Therefore, we only tested 1 fixation size for each design. In effect, changing the articular dimensions of the implant did not affect the dimensions of the pegs or keel.



**Figure 2** **A**, Transverse cross section through scapula with standard pegged implant design. **B**, Tolerance for error in anteversion was measured by rotating the implant until the fixation peg or keel perforated through the glenoid vault. **C**, Tolerance for error in retroversion was measured similarly. **D**, To quantify the potential for correction of retroversion deformity, the distance through which the implant could be medialized without perforation was measured. The corresponding angle at the medialized position was measured to be the degree of retroversion that could be corrected by that specific design.

### Virtual implantation

The glenoid implant models were imported into the MIMICS program and aligned along the scapular axis (Figure 2, A). The implant was then medialized along the direction of the scapular axis until the periphery of the implant was in 100% contact with the glenoid surface. This was done to simulate the surgical technique in which the glenoid face would be reamed to match the implant convexity. To determine the margin for error in orientation for each design,

each glenoid component was rotated in anteversion and retroversion (Figure 2, B and C), and the angles at which the pegs perforated the cortical surface were noted. To determine the amount of glenoid retroversion that could be corrected, each glenoid component was medialized in neutral version until the keel or one of the pegs perforated. The degree of retroversion corresponding to the medialization distance at perforation was recorded (Figure 2, D). Pilot virtual implantations and cadaveric implantations were performed to develop the protocol for the implantation technique. Three observers independently performed the virtual implantation. The intraclass correlation coefficient<sup>9</sup> was 0.92 (95% confidence interval, 0.86-0.96). A value of 1 indicates perfect agreement among observers.

### Angle measurements

A line was drawn connecting the center of the face of the glenoid implant to the tip of the scapular spine to determine the scapular axis. Another line drawn through the same point on the glenoid implant, but normal to the face, was used to determine the implant axis. The angle between the implant axis and scapular axis in the transverse plane was recorded as anteversion (implant face tilted anteriorly) or retroversion (implant face tilted posteriorly).

### Validation with cadaveric surgery

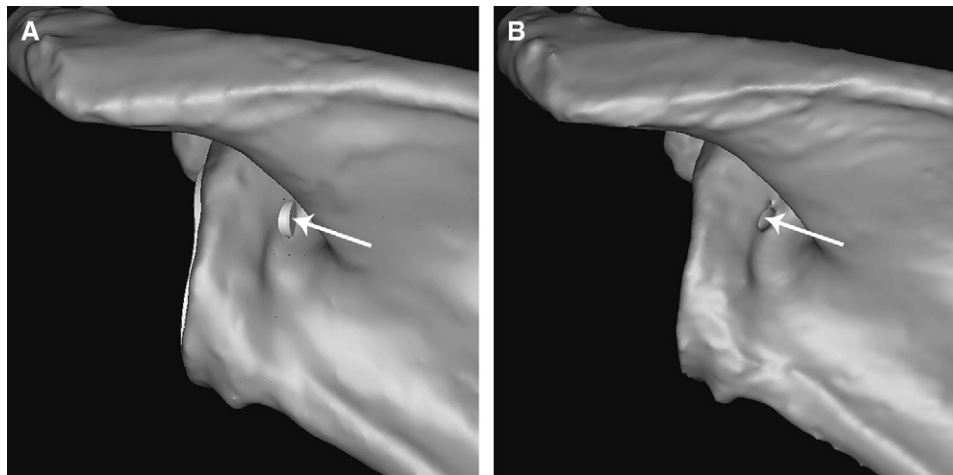
The accuracy of 3D-CT-reconstructed models has been previously reported. Kwon et al<sup>8</sup> showed that glenoid version measurements on 3D-CT-reconstructed models were within  $1^\circ \pm 0.7^\circ$  and glenoid surface width and length were within  $1.8 \pm 1.2$  mm and  $1.4 \pm 1.1$  mm, respectively, of those from cadaveric specimens. We also measured glenoid width and height on both cadaveric specimens and 3D-CT reconstructions, and the range of our measurement error was 0.7 to 2.7 mm. Cadaveric implantation ( $n = 7$ ) was used to confirm that the results of perforation seen on virtual implantation accurately represented reality. The same scapulae that perforated during cadaveric surgery (3/7) also perforated during the virtual surgery (Figure 3).

### Statistical analysis

The Fisher exact test was used to determine statistically significant differences in the incidence of perforation among the 3 implant designs. Repeated-measures analysis of variance with post hoc pair-wise Tukey comparisons was used to determine statistically significant differences in tolerance for anteversion error, retroversion error, and correction of glenoid retroversion deformity among designs.

## RESULTS

Mean glenoid version for the 40 scapulae was  $-3.23^\circ \pm 4.5^\circ$ . The incidence of perforation on 3D-CT preoperative templating was 8% for the modified pegged design and 13% for the keeled design compared with 18% for the standard pegged design (although this was not statistically significant). The modified pegged design had the highest tolerance



**Figure 3** **A**, Posterior view of glenoid area showing perforation of fixation peg (arrow) after virtual implantation of glenoid implant aligned along scapular axis. **B**, Posterior view of 3D-reconstructed CT scan of same scapula after cadaveric implantation showing location of perforation (arrow).

**Table I** Maximum anteversion or retroversion before cortical penetration for 3 designs

Prosthetic design	Anteversion tolerance	Retroversion tolerance
Pegged	9.5° ± 8.4°	21.2° ± 17.0°
Modified pegged	36.3° ± 39.3°	40.7° ± 29.6°
Keeled	4.9° ± 6.0°	20.0° ± 13.2°

Mean differences between groups were statistically significant ( $P < .001$ ).

**Table II** Maximum correction of glenoid retroversion before cortical penetration for 3 designs

Prosthetic design	Retroversion angle
Pegged	5.9° ± 5.6°
Modified pegged	11.0° ± 6.4°
Keeled	8.7° ± 6.9°

Mean differences between groups were statistically significant ( $P < .001$ ).

for perforation resulting from surgical error in anteversion or retroversion alignment (Table I).

Significantly, greater correction of glenoid retroversion (Table II) was possible with the modified pegged design (11.0° ± 6.4°) and the keeled implant (8.7° ± 6.9°). In 96% of cases, the peg perforation, which limited correction of retroversion, occurred in the posterior cortex. The incidence of perforation (in optimum placement along the scapular axis) was higher in smaller scapulae. The glenoid height, width, and length of scapula along the scapular axis were 21% ± 8.5% smaller in the cases that perforated compared with those that did not. This result was statistically significant for all 3 designs.

## DISCUSSION

Studies have attempted to study the fit of glenoid component designs.<sup>2</sup> However, they have focused mainly on the mismatch between the articular geometry of the implant and that of the native glenoid surface. One complication that has received very little attention is glenoid vault perforation by the fixation pegs or keel. Using the standard pegged design on 3D-CT reconstructions resulted in a moderate incidence of perforation (18% of cases). This result reflects the effect of the complex 3D geometry of the glenoid vault, the relatively small volume, and the nature of implant design.

The keeled design only perforated in 13% of cases, which was probably because the keel was more centrally located in the region of largest bone stock of the glenoid vault. There is a biomechanical advantage of fixation pegs over keels<sup>11</sup>; however, pegs may increase the risk for intraoperative perforation. Reducing the size of fixation pegs and clustering the pegs closer together also reduced the incidence of perforation (though not to a statistically significant degree). Our data indicate that it is possible to reduce the incidence of perforation by judiciously revising the peg design. Almost all cases of perforation occurred through the posterior cortex. Though not tested in this study, asymmetric peg placement, more anterior than in conventional designs, may further reduce the incidence of perforation.

The complex scapular anatomy and orientation make it difficult with current surgical techniques to orient the glenoid implant at precisely the desired version. Error in glenoid version alignment can result in a suboptimal position with increased potential for perforation. Each design was also evaluated to estimate

the margin of safety for perforation in the presence of suboptimal glenoid version. In general, all 3 implant designs were more tolerant of retroversion than of anteversion. This result was consistent with the fact that almost all cases of spontaneous perforation in the normal specimens used in our study occurred in the posterior cortex. In shoulders with severe glenoid retroversion (such as in osteoarthritis), the glenoid component may be more likely to perforate anteriorly, if glenoid version is not corrected by eccentric reaming. Although the keeled design had a low initial incidence of perforation, it was not very tolerant of malalignment (tolerance to anteversion was  $<5^\circ$ ), which was a result of the size of the keel that requires central placement within the glenoid vault.

Arthritis of the shoulder is most commonly associated with wear in the posterior part of the glenoid, resulting in increased retroversion.<sup>13</sup> It is recommended that this retroversion be corrected to optimize the position of the humeral head and the transfer of stresses to the implant-cement-bone interface.<sup>6,10</sup> However, correction of wear-related glenoid retroversion involves eccentric reaming and medializing the glenoid component or bone grafting or cement/implant augmentation to build up the missing bone stock. Excessive medialization increases the potential for glenoid perforation, whereas bone grafting and augmentation add complexity to the surgical procedure and can increase the potential for failure. We assessed the degree of correction of retroversion that was possible with each implant design. The amount of correction possible with eccentric reaming was lower than anticipated and varied significantly by implant design. The keeled and modified pegged designs permitted greater correction of retroversion before perforation than the standard pegged design. Preoperative knowledge of the amount of retroversion and the degree of correction possible in specific patient anatomy can be invaluable in selecting the appropriate design or in planning for bone grafting.

Only scapulae that were free of arthritis were studied. Arthritis distorts the anatomy and may result in a different incidence of perforation. Aligning the implant in arthritic shoulders is more difficult, because the wear and loss of cartilage and bone stock that occur may increase the incidence of perforation. The dimensions of the fixation pegs or keel were not changed for different implant sizes, which may be partly responsible for the increased potential for perforation in smaller scapulae. Because we constructed implant models based on mean measurements made from commercially available designs, our results may be not be applicable to any specific manufacturer's design. However, the conclusion that reducing the

footprint of the fixation pegs increases potential for retroversion correction, as well as tolerance for version error, is valid. Perforation through the cortex is only one criterion of failure. Impingement of the fixation pegs against the inner cortex could also affect stress transfer but was not analyzed in this study. Finally, we did not test the effect of the implant fixation design on the biomechanics of fixation. Changing the size and shape of fixation pegs may alter the strength of fixation, which is a part of our ongoing research.

In summary, we assessed the potential for perforation in 3 implant designs. We also measured the tolerance for malalignment, as well as the potential to correct for retroversion deformity of the glenoid. These results may be used to improve implant fixation designs. Furthermore, these results emphasize the need for accurate preoperative templating and for developing alignment guides or surgical navigation tools for shoulder arthroplasty.

## REFERENCES

1. Bohsali KI, Wirth MA, Rockwood CA Jr. Complications of total shoulder arthroplasty. *J Bone Joint Surg Am* 2006;88:2279-92.
2. Checroun AJ, Hawkins C, Kummer FJ, Zuckerman JD. Fit of current glenoid component designs: an anatomic cadaver study. *J Shoulder Elbow Surg* 2002;11:614-7.
3. Farmer KW, Hammond JW, Queale WS, Keyurapan E, McFarland EG. Shoulder arthroplasty versus hip and knee arthroplasties: a comparison of outcomes. *Clin Orthop Relat Res* 2007:183-9.
4. Friedman RJ, Hawthorne KB, Genez BM. The use of computerized tomography in the measurement of glenoid version. *J Bone Joint Surg Am* 1992;74:1032-7.
5. Gregory T, Hansen U, Emery RJ, Augereau B, Amis AA. Developments in shoulder arthroplasty. *Proc Inst Mech Eng [H]* 2007;221:87-96.
6. Hopkins AR, Hansen UN, Amis AA, Emery R. The effects of glenoid component alignment variations on cement mantle stresses in total shoulder arthroplasty. *J Shoulder Elbow Surg* 2004;13:668-75.
7. Klepps S, Chiang AS, Miller S, Jiang CY, Hazrati Y, Flatow EL. Incidence of early radiolucent glenoid lines in patients having total shoulder replacements. *Clin Orthop Relat Res* 2005:118-25.
8. Kwon YW, Powell KA, Yum JK, Brems JJ, Iannotti JP. Use of three-dimensional computed tomography for the analysis of the glenoid anatomy. *J Shoulder Elbow Surg* 2005;14:85-90.
9. McGraw KO, Wong SP. Forming inferences about some intraclass correlation coefficients. *Psychol Methods* 1996;1:30-46.
10. Nyffeler RW, Sheikh R, Atkinson TS, Jacob HA, Favre P, Gerber C. Effects of glenoid component version on humeral head displacement and joint reaction forces: an experimental study. *J Shoulder Elbow Surg* 2006;15:625-9.
11. Pearl ML. Proximal humeral anatomy in shoulder arthroplasty: implications for prosthetic design and surgical technique. *J Shoulder Elbow Surg* 2005;14:99S-104.
12. van de Sande MA, Brand R, Rozing PM. Indications, complications, and results of shoulder arthroplasty. *Scand J Rheumatol* 2006;35:426-34.
13. Walch G, Badet R, Boulahia A, Khoury A. Morphologic study of the glenoid in primary glenohumeral osteoarthritis. *J Arthroplasty* 1999;14:756-60.