

Posterior capsular fibrosis in professional baseball pitchers: case series of MR arthrographic findings in six patients with glenohumeral internal rotational deficit

Arash D. Tehranzadeh^{a,*}, Jan Fronek^b, Donald Resnick^c

^aUCSD Musculoskeletal Radiology, Los Angeles, CA 90024, USA

^bDepartment of Orthopaedic Surgery, La Jolla, CA 92037, USA

^cUCSD/VA San Diego Health Care System, San Diego, CA 92162, USA

Received 15 April 2007; accepted 5 May 2007

Abstract

In the high-performance athlete, acquired thickening of the posterior joint capsule is a proposed etiology for glenohumeral internal rotational deficit (GIRD). The purpose of this study was to present our MR arthrographic imaging observations of posterior capsular thickening in professional baseball players who present with reduced throwing velocity related to pain and clinical findings of internal rotational deficit of the glenohumeral joint. Our observations of MR imaging features in patients with clinical and arthroscopic manifestations of GIRD lesions include articular surface partial thickness tears of the supraspinatus and infraspinatus tendons, superoposterior subluxation of the humeral head and SLAP tears of the labrum. Although no empiric standard currently exists for the axial dimension thickness of the shoulder capsule, we have observed a thickened appearance of the posterior band of the inferior glenohumeral ligament in these patients. © 2007 Elsevier Inc. All rights reserved.

Keywords: Shoulder; Joint; MR Imaging; Musculoskeletal imaging; Sports medicine

1. Introduction

The ability to achieve high throwing velocities may be hindered in athletes with chronic micro-trauma that results in capsular thickening of the posterior band of the inferior glenohumeral ligament and this has been postulated as the inciting factor in the chain of events that eventually leads to a “dead arm” in the American baseball pitcher [1]. As a consequence of posterior capsular thickening, humeral head subluxation occurs resulting in a wider rotational arc of the greater tuberosity during the throwing cycle. The athlete

experiences pain and instability related to posterior impingement of the articular surface of the rotator cuff between the greater tuberosity and the posterosuperior portion of the glenoid labrum. Also, there is increased rotational torque in the proximal biceps tendon and anchor, and this torque ultimately may lead to superior labrum anterior and posterior (SLAP) lesions (Fig. 1A and B) [1,2].

This case series of six baseball pitchers with symptoms of glenohumeral internal rotational deficit (GIRD) verifies that the arthroscopic and pathokinematic findings of posterior impingement and glenohumeral internal rotational deficit can be appreciated on MR imaging. The MR findings of posterior impingement in the “throwing shoulder” has previously been described and includes subchondral cyst formation in the posterior humeral head, articular surface tears of the rotator cuff and SLAP tears of the labrum. This case series also proposes new MR findings in athletes

* Corresponding author. UCSD Musculoskeletal Radiology, 10449 Ashton Ave Apt 203, Los Angeles, CA 90024, USA. Tel.: +1 949 798 9776.

E-mail addresses: adtehran@yahoo.com (A.D. Tehranzadeh), fronek.jan@scrippshealth.org (J. Fronek), dresnick@ucsd.edu (D. Resnick).

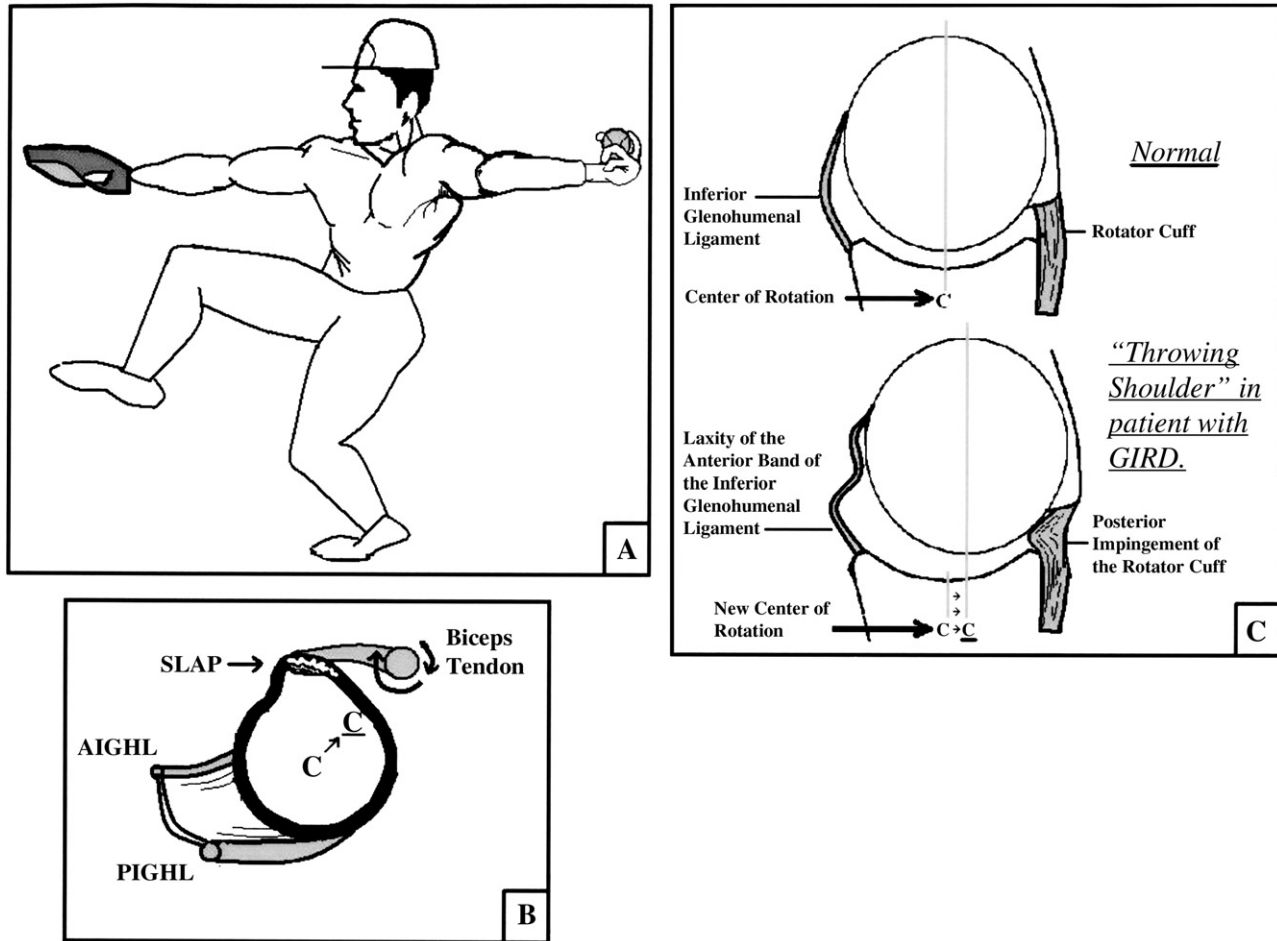


Fig. 1. Pathology in the throwing shoulder. (A) Schematic pose of the baseball pitcher in the early or “cocking” phase of throwing with the shoulder in abduction and external rotation (ABER). (B) Sagittal oblique view of the glenoid fossa shows a thickened posterior inferior glenohumeral ligament (PIGHL), posterosuperior migration of the center of humeral head rotation (C) and rotational torque on the proximal biceps tendon and anchor leading to a SLAP tear. (C) Coronal oblique view in the ABER position that demonstrates posterosuperior subluxation of the humeral head manifested by posterior migration of the center of rotation (C), internal impingement of the rotator cuff between the greater tuberosity and the posterosuperior portion of the glenoid cavity, and laxity of the anterior inferior glenohumeral ligament (AIGHL) as a consequence of the humeral head subluxation.

with GIRD, which previously has not been described in the radiology literature. Clinically, much attention has been given to the altered arthrokinematics in the throwing

shoulder with a thickened posterior capsule, yet no clear standard for a normal shoulder capsule thickness exists in the radiology literature [1–3].

Table 1
Baseball players with symptoms of GIRD

Patients	Age (years)	Rotator cuff undersurface tear	Labral tear	Athroscopically proven	Appearance of posterior capsular thickening
Patient 1	22	Low-grade partial tear, supraspinatus and infraspinatus	SLAP 1	Yes	Yes
Patient 2	33	Moderate 40%, posterior fibers of supraspinatus and infraspinatus	SLAP 2	Yes	Yes
Patient 3	27	Low grade, infraspinatus	Posterior superior fraying	No	Yes
Patient 4	24	Low grade, supraspinatus	Posterior fraying	No	Yes
Patient 5	48	Low grade, supraspinatus and infraspinatus	SLAP tear with extension into anterior labrum	Yes	Yes
Patient 6	23	Low grade, supraspinatus	Posterior fraying	Yes	Yes

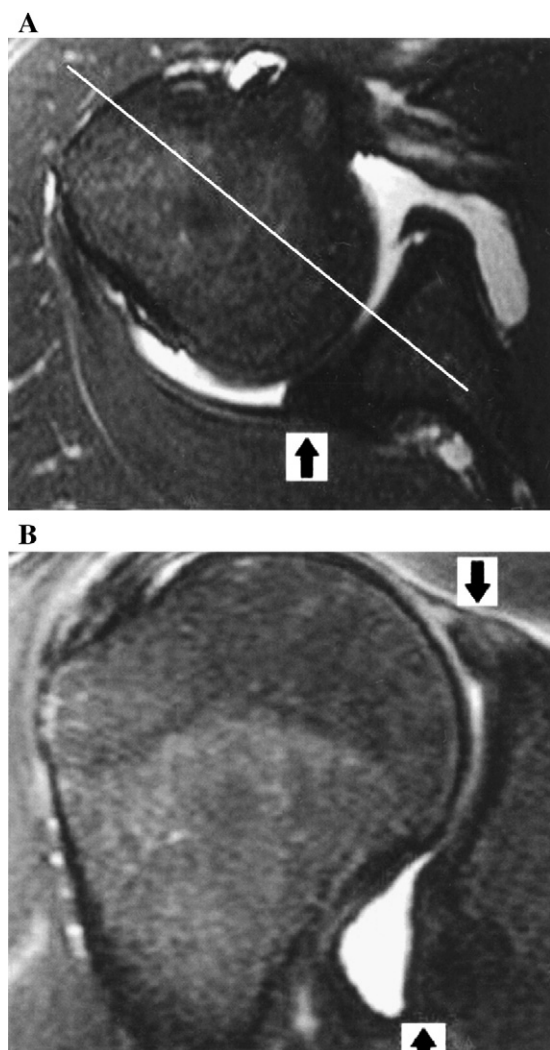


Fig. 2. A 27-year-old baseball player with shoulder pain. (A) T2 turbo spin echo fat saturation MR arthrographic axial image demonstrates a thickened posterior capsule at the posterior capsular labral junction (arrows). The thin white line demarcates the normal center of rotation, which is shifted to a new equilibrium in this patient and manifested by posterior subluxation of the humeral head with respect to the glenoid in this image. (B) T2 turbo spin echo fat saturation MR arthrographic coronal oblique image of the same patient shows thickening of the axillary pouch (arrow) and a frayed appearance of the posterosuperior labrum (arrow).

1.1. Case report

A retrospective review of MR arthrograms, medical records and arthroscopy reports was performed in baseball players at our institution resulting in six professional athletes with symptoms of GIRD. All patients were seen and treated at one of our hospitals by one of four orthopedic specialists in sports medicine. The age range in these six patients was from 22 to 48 years of age (Table 1) at the time of imaging. All of the athletes had played or were playing at the professional level and in all patients the dominant shoulder was involved. None of the patients had a history of a major traumatic event or prior shoulder surgery. The most severely involved patient reported a decreased throwing

velocity to 40% of the baseline maximum. Pain was maximal in all patients when the arm was placed in the abducted, externally rotated position (ABER), and a decrease in internal rotation of the glenohumeral joint was clinically reported in all patients. Clinical evaluation for SLAP tears was positive in all patients using the O'Brien's test. This maneuver is performed while the arm is forward flexed to 90°, adducted to 20° and internally rotated to maximum. A positive O'Brien's test suggests a labral tear when a downward force on the forearm incites pain while in pronation and the pain is reduced in supination.

In this series, shoulder MR arthrograms were performed on a 1.5-T Symphony scanner (Siemens). All patients retrospectively reviewed had undergone a fluoroscopically guided direct anterior approach for intra-articular administration of ~12 ml of 1:200 dilution of gadolinium (GE, Omniscan). At our institution, patients are routinely imaged in the supine position and with the shoulder in external rotation. All MR arthrogram images were retrospectively reviewed in consensus by two American Board-certified radiologist with subspecialization in musculoskeletal imaging. MR imaging examinations demonstrated arthroscopic proven SLAP tears in four patients and, in the other two patients, posterior labral fraying. Undersurface tears of the rotator cuff were seen in all patients (Table 1).

Imaging features were defined with particular attention to the rotator cuff, labrum and joint capsule. Partial thickness rotator cuff tears were defined on the basis of their vertical component and characterized as low grade (<3 mm), moderate grade (3–6 mm) and high grade (>6 mm) [4]. Labral pathology was defined by fraying but with no frank tear of the articulating surface of the superior portion of the glenoid labrum and with an intact biceps tendon (SLAP I), detachment of the labral-biceps complex from the superior glenoid rim (SLAP II), bucket handle tear of the superior labrum (SLAP III), or as bucket handle tear with extension into the biceps tendon (SLAP IV) [5]. Our review of the literature did not yield an empirical standard of measurement for a normal or thickened posterior shoulder joint capsule.

The images demonstrated posterosuperior subluxation of the humeral head, which was best appreciated on the axial images (Figs. 2A and 4A) and manifested as a posterosuperior relationship of the medial articulating surface of the humeral head with respect to the glenoid rim. SLAP tears of the labrum (Figs. 2B, 3B and 4B) and undersurface tears of the rotator cuff (Figs. 3B and 4B, D and E) were well seen and correlated with the findings seen in those patients who had undergone arthroscopy (Table 1). Associated findings included subchondral cyst formation in the posterolateral aspect of the humeral head (Fig. 4D).

This case series proposes new MR imaging findings in the setting of GIRD not previously reported in the literature. Based on our experience interpreting MR images in patients without GIRD, we subjectively identified a thickened appearance of the glenohumeral joint capsule.

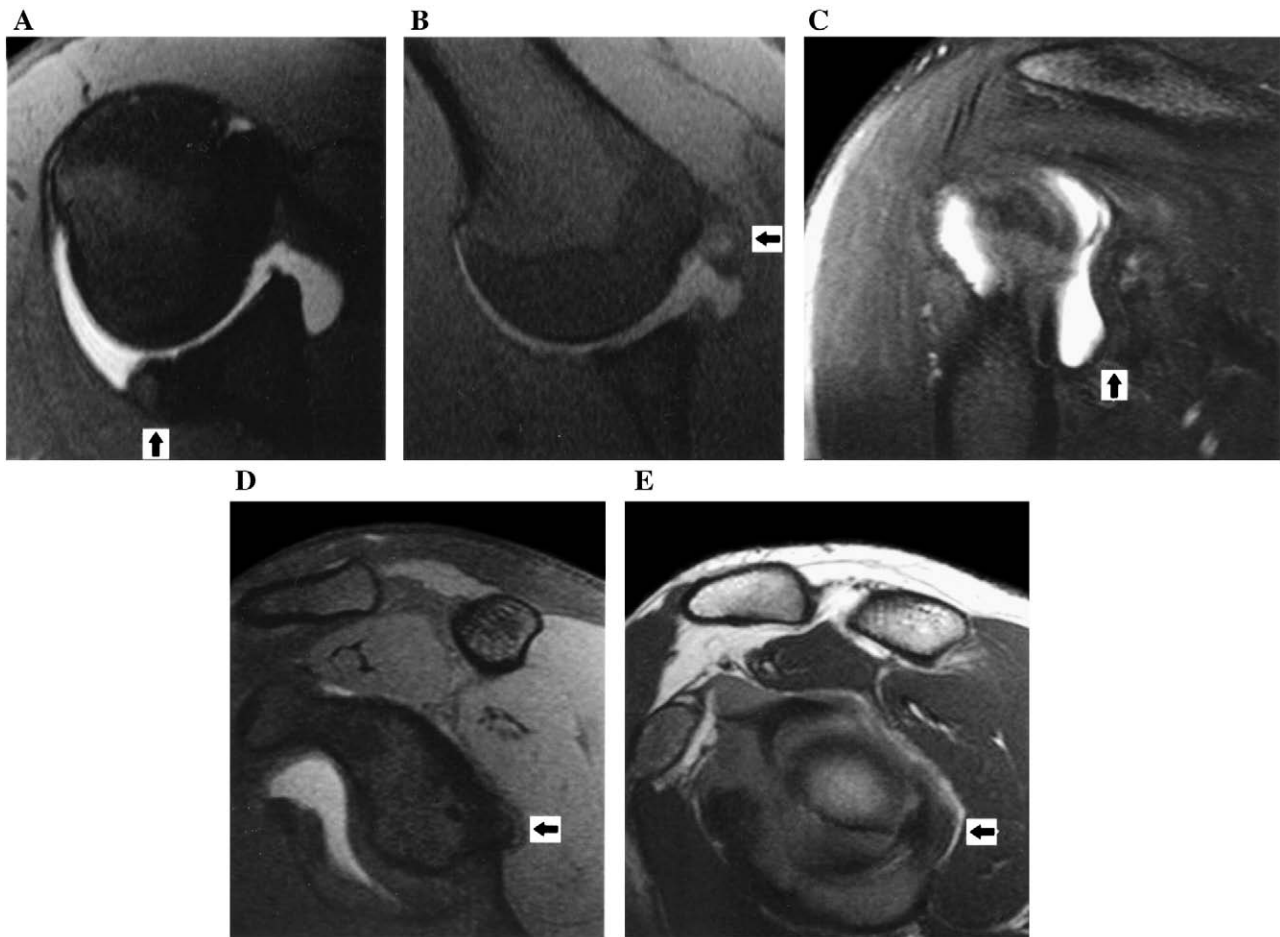


Fig. 3. A 22-year-old baseball player with shoulder pain. (A) Axial T1 spin echo fat saturation MR arthrographic image shows a thickened posterior capsulolabral junction. (B) ABER T1 spin echo fat saturation MR arthrographic image demonstrates an arthroscopically proven undersurface partial tear of the infraspinatus tendon (arrow). (C) Coronal oblique T2 spin echo fat saturation MR arthrogram shows a thickened posterior capsule (arrow). (D and E) Sagittal oblique T1 spin echo MR arthrographic images with and without fat saturation, respectively, show a thickened posterior capsule.

Specifically, this thickened band of the inferior glenohumeral ligament was best appreciated in the transaxial and coronal oblique images, appearing as a band of low signal in the region of the posterior labrum at the capsulolabral junction (Figs. 2–4). A thickened capsule at the axillary recess of the joint on coronal images was also evident in all cases. These findings were less evident on the sagittal and ABER projections. Given the current lack of an empiric standard of joint capsule measurement, the appearance of a thickened inferior glenohumeral ligament is based on our own clinical and imaging observation.

2. Discussion

The concept of posterior impingement was first introduced by Walch et al. [6] in 1992. This was further evaluated by Jobe [7,8] who applied it to the analysis of throwers. Specifically, when the athlete is in a throwing position with the shoulder in 90° of abduction and $\geq 90^\circ$ of external rotation, the posterosuperior portion of the glenoid

rim and greater tuberosity cause impingement of the rotator cuff and the posterosuperior aspect of the labrum. In 2003, Burkhart et al. [1] further described impingement in the throwing shoulder as a cascade of pathology that begins initially as fibrosis of the posterior capsule of the glenohumeral joint, specifically the inferior posterior glenohumeral ligament. Under this cascade, the fibrosis of the posterior capsule is postulated as a consequence of chronic traumatic micro-tears. The thickened posterior capsule results in posterosuperior subluxation of the humeral head. Due to a wider rotational arc of the greater tuberosity, the athlete is subjected to impingement of the rotator cuff between the posterosuperior portion of the glenoid rim and the humeral head. Hence, the labrum is also subjected to injury. In this new position of the humeral head, labral injury is also exacerbated by increased rotational torque on the biceps tendon, the latter contributing to superior labral displacement (Fig. 1). Burkhart termed this effect the “peel-back” mechanism as viewed on arthroscopy when the arm is placed in the ABER position and the rotational torque of the biceps tendon peels the labrum

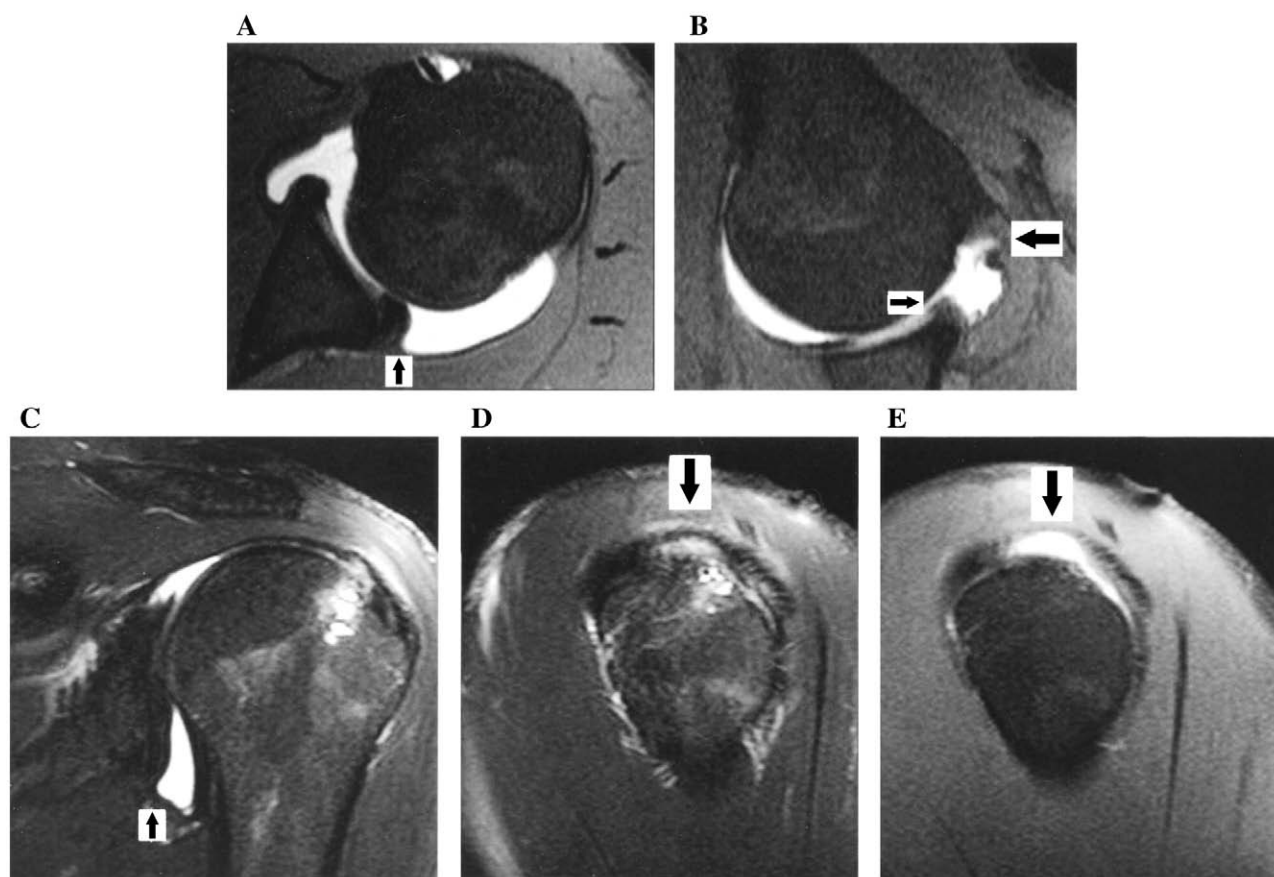


Fig. 4. A 23-year-old baseball player with shoulder pain. (A) Axial T1 spin echo fat saturation MR arthrographic images show posterior subluxation of the humeral and thickening of the posterior capsule at the capsulolabral junction (arrow). (B) ABER T1 spin echo fat-suppressed MR arthrographic image shows an arthroscopically proven undersurface tear of the supraspinatus tendon (arrow) and fraying of the superior labrum (small arrow). (C) Coronal oblique T2 turbo spin echo fat-suppressed MR arthrographic image shows superior humeral head subluxation and a thickened posterior capsule (arrow). Note also the subchondral cysts in the posterolateral humeral head, which is an associated finding in posterior impingement. (D and E) Sagittal oblique T2 turbo spin echo fat saturation (D) and T1 spin echo fat saturation (E) MR arthrographic images respectively demonstrate undersurface tears of the rotator cuff (arrows).

medially (toward the direction of the thorax) off the superior glenoid rim. An association with Type II SLAP lesions was further supported by a cadaveric study in 10 shoulders with a simulated posterior capsular contracture [2].

In patients with posterior impingement, a constellation of MR imaging findings has been reported and include undersurface tears of the supraspinatus or infraspinatus tendon, or both tendons, cystic changes in the posterior aspect of the humeral head, and posterosuperior labral pathology [9,10]. Routine MR imaging is not reliable in the evaluation of posterior impingement, and MR arthrography with ABER positioning is beneficial [11].

Our study is intended to emphasize the imaging findings in the throwing shoulder in patients with shoulder impingement. A caveat of our investigation was the presence of a thickened appearance of the shoulder capsule in those athletes who also presented with a chief complaint of decreased throwing velocity attributed to pain, symptoms and signs of posterior impingement and GIRD. Our review did not account for patients with similar symptoms who lacked these imaging findings. To our knowledge, an

objective imaging criteria of normal shoulder capsule thickness has not been established and the imaging findings presented in this investigation warrant further evaluation, preferably with a control model. The thickened posterior inferior glenohumeral ligament is best seen in the axial and coronal oblique images. In addition to a thickened capsule, the subsequent features described in the Burkhart model were also seen including posterosuperior subluxation of the humeral head, undersurface tears of the rotator cuff, SLAP tears and associated subchondral cysts in the superolateral aspect of the humeral head.

This case series was limited by lack of arthroscopic correlation in two cases. Clinically, an acceptable clinical level of GIRD is $<20^\circ$ or $<10^\circ$ of the total rotation when compared with the nonthrowing shoulder [1]. Being a retrospective study, the medical records did not give a numerical assessment of the degree of GIRD in all patients included in the series. The patients did not have CT scans in order to assess for the presence of calcification in the posterior capsule to exclude the presence of a Bennett lesion. Furthermore, a selective prospective analysis would be useful

to further investigate this topic in order to establish a normal standard of capsular measurement by comparing capsular thickness in patients with GIRD to normal subjects.

3. Conclusion

The pathoanatomic kinematics of the throwing shoulder is a complex process that has been postulated to arise from a chronic thickening of the posteroinferior glenohumeral ligament. This finding can be seen with MR arthrography in the region of the capsulolabral junction. It is associated with GIRD. Additionally, posterosuperior subluxation of the humeral head, articular-sided tears of the rotator cuff and SLAP lesions are evident in these patients.

References

- [1] Burkhart S, Morgan C, Kibler B. The disabled throwing shoulder: spectrum of pathology: Part I. Pathoanatomy and biomechanics. *Arthroscopy* 2003;19(4):404–20.
- [2] Grossman M, Tibone J, McGarry M, Schneider D, Veneziani S, Lee T. A cadaveric model of the throwing shoulder: a possible etiology of superior labrum anterior-to-posterior lesions. *J Bone Joint Surg Am* 2005;87:824–31.
- [3] Tyler T, Nicholas S, Roy T, Gleim G. Quantification of posterior capsule tightness and motion loss in patients with shoulder impingement. *Am J Sports Med* 2000;28(5):668–73.
- [4] Elmer H. Diagnosis and treatment of incomplete rotator cuff tears. *Clin Orthop* 1990;254:64–74.
- [5] De Maeseneer M, Van Roy F, Lenchik L, Shahabpour M, Jacobson J, Kyung R, Handelberg F, Osteaux M. CT and MR arthrography of the normal and pathologic anterosuperior labrum and labral–bicipital complex. *Radiographics* 2000;20:S67–S81.
- [6] Walch G, Boileau P, Noel E, Donell ST. Impingement of the deep surface of the supraspinatus tendon on the posterosuperior glenoid rim: an arthroscopic study. *J Shoulder Elbow Surg* 1992;1:238–45.
- [7] Jobe CM. Posterior superior glenoid impingement: expanded spectrum. *Arthroscopy* 1995;11:530–6.
- [8] Paley KJ, Jobe FW, Pink MM, et al. Arthroscopic findings in the overhand throwing athlete: evidence for posterior internal impingement of the rotator cuff. *Arthroscopy* 2000;16:35–40.
- [9] Giaroli E, Major N, Higgins L. MRI of internal impingement of the shoulder. *AJR Am J Roentgenol* 2005;185:925–9.
- [10] Tirman PF, Bost FW, Garvin GJ, Peterfy CG, Mall JC, Steinbach LS, Feller JF, Crues JV. Posterosuperior glenoid impingement of the shoulder: findings at MR imaging and MR arthrography with arthroscopic correlation. *Radiology* 1994;193:431–6.
- [11] Roger B, Skaf A, Hooper AW, Lektrakul N, Yeh L, Resnick D. Imaging findings in the dominant shoulder of throwing athletes: comparison of radiography, arthrography, CT arthrography, and MR arthrography with arthroscopic correlation. *AJR Am J Roentgenol* 1999;172(5):1371–80.